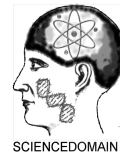



British Journal of Medicine & Medical Research
2(2): 254-259, 2012

SCIENCEDOMAIN *international*
www.sciencedomain.org



Sudden Bilateral Blindness Following Massive Uterine Bleeding: Reports of 2 Cases

Chinyere Nnenne Pedro-Egbe^{1*} and Elizabeth Awoyesuku¹

¹Department of Surgery (Ophthalmology Unit), College of Health Sciences,
University of Port Harcourt, Nigeria.

Case Study

Received 23rd November 2011
Accepted 17th March 2012
Online Ready 29th March 2012

ABSTRACT

Background: Most cases of sudden blindness are due to vascular causes. Ischemic optic neuropathy is a rare cause of blindness reported most commonly in association with collagen-vascular diseases, infectious processes, and systemic hypotension related to massive exsanguinating hemorrhage.

Aim: To report 2 cases of bilateral complete visual loss following massive uterine hemorrhage.

Case reports: Case 1 is a 23 year-old unmarried female student who first presented at our Eye Clinic on account of bilateral visual loss of 5 months duration. She had, had a septic abortion and profuse bleeding per vaginum for over a week before visual loss. Case 2 is a 39 year-old unmarried school teacher who presented on account of sudden bilateral visual loss of two months duration following myomectomy. Postoperatively, patient was transfused 4 pints of blood.

Conclusion: Since sudden visual loss could follow non-ocular surgical procedures, surgeons must always be on the alert and ensure they avoid conditions that could predispose a patient to optic nerve ischemia; conditions such as perioperative drops in systemic blood pressure and hematocrit values. Normotension during and after surgery, is therefore vital in preventing optic nerve ischemia.

Keywords: Sudden bilateral blindness; massive uterine bleeding.

1. INTRODUCTION

Sudden visual loss is a rare but devastating complication of massive hemorrhage which could occur intra-operatively (Frederico et al., 2006) postoperatively (Sadaba et al., 2006) in the postpartum period (Ranjana and Sanjiv, 1997) or follow hypovolemic states (Katz, 1994; Connolly et al., 1994; Petrone, 2002; Remigio and Wertenbaker, 2000). It has also been reported with systemic hypotension, most often in the context of massive hemorrhage during major surgery (Hollenborst and Wagener 1950; Dranie et al., 1973; Johnson et al., 1987) or where hypotension is deliberately induced to allow for an uneventful surgery (such as spine surgery) (Katz, 1994). Sudden visual loss has been ascribed to ischemic optic neuropathy by various studies (Frederico et al., 2006; Sadaba et al., 2006; Ranjana and Sanjiv, 1997; Katz, 1994; Connolly et al., 1994; Petrone, 2002; Remigio and Wertenbaker, 2000). Ischemic optic neuropathy is usually associated with giant cell (temporal) arteritis as well as with systemic hypertension, diabetes mellitus, hyperlipidemia, systemic lupus erythematosus and herpes zoster ophthalmicus (Johnson et al., 1987; Hayreh, 1981; Isayama et al., 1983; Isayama and Takashi, 1983). The common pathology in ischemic optic neuropathy is hypoperfusion of the optic nerve which causes axonal injury and/or neuronal death, with resultant loss of vision.

Visual loss after anesthesia and surgery is a rare, but unexpected and devastating complication. The incidence of visual loss postoperatively has been estimated at 0.1% (Boghen and Glaser, 1975; Kay, 1991), some retrospective reviews found it to be about 0.002% (Walkup and Murphy 1952).

We report on two cases of what we believe to be ischemic optic neuropathy following massive intra-uterine hemorrhage.

2. CASE REPORTS

2.1 Case 1

A.L is a 23 year-old unmarried female student who first presented at the Eye Clinic of our hospital (University of Port Harcourt Teaching Hospital (UPTH)) in March 2008, on account of gradual bilateral visual loss of 5 months duration. She had, had a septic abortion with the help of a traditional herbalist who inserted some herbs into her vagina from where she started bleeding profusely. The bleeding lasted for about a week after which she noticed a gradual but progressive diminution of vision both eyes over the course of two weeks and became totally blind by the third week. Throughout this period, the patient was not evaluated by any physician nor was she transfused any blood. There was no past history of ocular disease and she was not a known hypertensive or diabetic.

At presentation, her visual acuities were No Perception of Light (NPL) in both eyes and her intra-ocular pressures were normal (RE=12mmHg; LE=13mmHg). She had an upward rolling movement of the eyeballs and her pupils were fully dilated and unreactive. She also had bilateral optic atrophy (fig. 1) with macular edema. Her blood pressure was 110/70mmHg, Full Blood Count (FBC) was essentially normal except for a slightly reduced hemoglobin level (9g/dL) and blood sugar was normal. Her lipid profile was also within normal limits.

Patient was started on high dose steroids (prednisolone 40mg daily) which was tailed off after one month, but vision remained NPL in both eyes 3 months after presentation. She has since been lost to follow up.

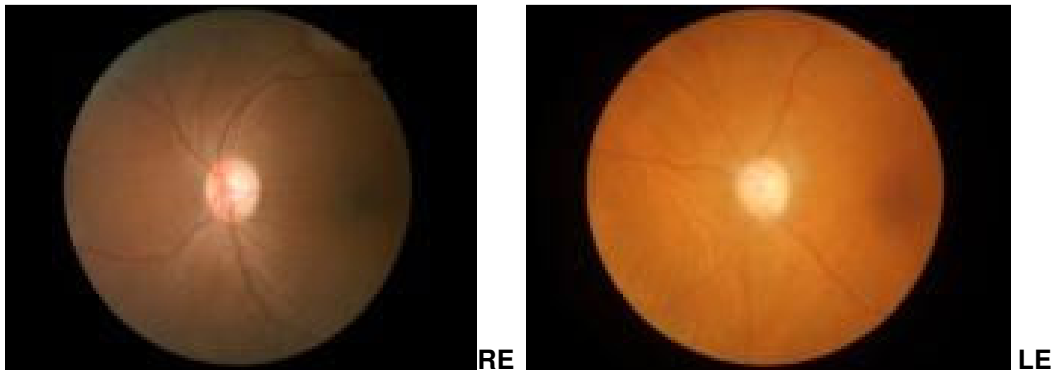


Fig.1. Shows bilateral Optic atrophy

2.2 Case 2

U.I is a 39 year-old unmarried school teacher who presented at our clinic in October 2009 on account of sudden loss of vision both eyes two months prior to presentation. Patient had undergone myomectomy (under general anesthesia) in a private clinic in Umuahia (South-Eastern Nigeria) and on waking up from anesthesia, discovered she could no longer see with both eyes. Postoperatively, she was transfused 4 pints of blood because of excessive blood loss during the surgery. Patient was not a known diabetic or hypertensive and she was not on any drugs prior to surgery.

At presentation, patient appeared anemic and had visual acuities of No Perception of Light (NPL) in both eyes. Her intra-ocular pressures (RE=16mmHg: LE=16mmHg) and blood pressure were normal (BP= 110/80mmHg). Further examination revealed dilated unreactive pupils, pale discs and a cup:disc ratio of 0.6 in both eyes; the rest of the fundal examination was normal (fig. 2). Full Blood Count (FBC) revealed a hemoglobin level of 7g/dL. Fasting Blood Sugar and lipid profiles were within normal limits.

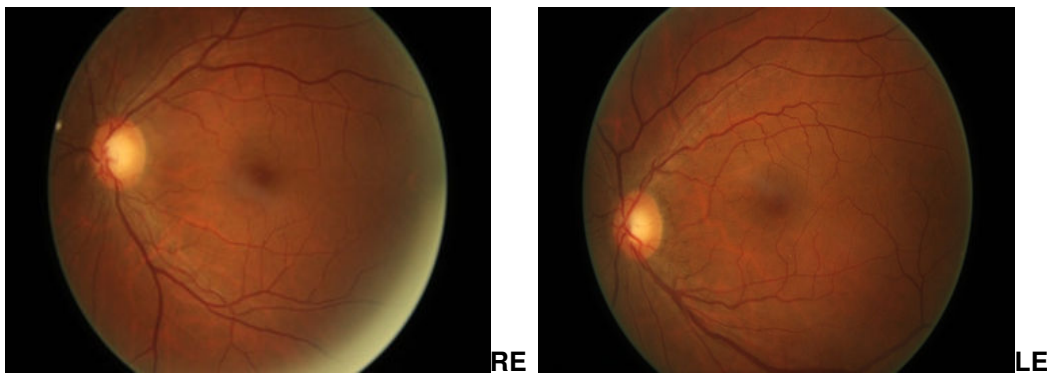


Fig. 2. Shows mild cupping of both right and left discs; other details are normal

Patient was placed on high dose steroids (prednisolone 40mg daily) which was tailed off after one month, but vision remained NPL in both eyes two months after presentation. She was thereafter lost to follow-up when there was no improvement in her visual status.

3. DISCUSSION

Visual loss following surgery is rare but when it occurs, it is most commonly due to cerebrovascular events which could cause infarction of the visual tracts with resultant loss of vision. Although some series have cited an incidence of postoperative visual loss as approximately 0.1% (Boghen and Glaser, 1975; Kay, 1991), some retrospective reviews found it to be about 0.002% (Walkup and Murphy 1952).

Ischemic optic neuropathy is the most common reported type of postoperative visual loss (Brown et al., 1994). In some reviews, ischemic injury to the optic nerve is said to account for about 24% of all cases of post-operative visual loss (Brown et al., 1994). While the intracranial and intracranial segments of the optic nerve possess a rich vascular supply, the anterior and posterior segments are significantly less well vascularized and hence are far more commonly subject to injury from ischemic events. Although anterior ischemic optic neuropathy is more common overall, posterior ischemic optic neuropathy is reported more frequently in postoperative patients (Alfano et al., 1957; Chisholm, 1969). In reported cases, a strong link has been established between ischemic optic neuropathy and severe hypotension (Waybright et al., 1982; Johnson, 1987). Ischemic optic neuropathy (ION) describes all presumed ischemic causes of optic neuropathy and is divided into two types; anterior ischemic optic neuropathy (AION) characterized by visible optic disc changes and posterior ischemic optic neuropathy (PION), in which no abnormality of the optic disc is evident.

AION could be arteritic; (caused by severe vasculitis) as in giant cell arteritis or non-arteritic. Nonarteritic anterior ischemic optic neuropathy is the result of the interruption of oxygen supply to the optic nerve head anterior to the lamina cribrosa, and the major contributing factors include failure of perfusion pressure resulting from a severe drop in blood (such as in systemic hemorrhage and surgical hypotension), critical decline of oxygen-transport by the blood (such as in severe anemia due to blood loss), and increased resistance to blood flow such as in atherosclerosis, polycythemia, and small optic disc (Kenkel et al., 2004). Posterior ischemic optic neuropathy, on the other hand, usually occurs in the setting of severe anemia and hypotension caused by hemorrhage from surgery and gastrointestinal bleeding, even in healthy subjects with no systemic vascular risk factors (Murphy, 2003).

The treatment of PION remains unclear, but if initiated within the first 48 hours, high-dose steroids in combination with osmotic diuretics are known to decrease the optic nerve edema and assist the residual blood supply to the intraorbital portion of the optic nerve (Feit et al., 1984). Systemic high-dose steroid therapy has been used successfully in the management of non-trauma patients (Lee, 1995).

However, other authors report no salvage of vision after steroid therapy (Isayama and Takashi., 1983; Shimo-Oku and Miyakazi., 1984; Boghen and Glaser, 1975) and thus steroid therapy for PION remains controversial. Both our patients probably have non-arteritic anterior ION because of the fundal changes which included optic atrophy and macular edema in the first case and disc palor in the second case.

4. CONCLUSION

Since sudden visual loss could follow non-ocular surgical procedures, surgeons must always be on the alert and ensure they avoid conditions that could predispose a patient to ischemia;

conditions such as perioperative drops in systemic blood pressure and hematocrit values. Normotension during and after surgery, is vital in preventing optic nerve ischemia.

COMPETING INTERESTS

Authors have declared that no competing interests exist.

REFERENCES

- Alfano, J.E., Fabritius, R.E., Garland, M.A. (1957). Visual loss following mitral commissurotomy. *Am J Ophthalmol*, 44, 213-216.
- Boghen, D.R., Glaser, J.S. (1975). Ischemic optic neuropathy: the clinical profile and history. *Brain*, 98, 689-708.
- Brown, R.H., Schauble, J.F., Miller, N.R. (1994). Anemia and hypotension as contributors to perioperative loss of vision. *Anesthesiology*, 80, 222-226.
- Chisholm, I.A. (1969). Optic neuropathy of recurrent blood loss. *Br J Ophthalmol*, 53, 289-295.
- Connolly, S.E., Gordon, K.B., Horton, J.C. (1994). Salvage of vision after hypotension-induced ischemic optic neuropathy. *Am J Ophthalmol.*, 117, 235-242.
- Dranie, S.M., Morgan, R.W., Sweeney, W.P. (1973). Shock induced optic neuropathy. *N Engl J Med.*, 288, 392.
- Frederico, C.M., Leonardo, P.C., Mário Luiz R.M. (2006). Bilateral visual loss after liposuction: case report and review of the literature. *Clinics*, 61, 5, São Paulo.
- Feit, R.H., Tomsak, R.L., Ellemberger, C. (1984). Structural factors in the pathogenesis of ischemic optic neuropathy. *Am J Ophthalmol*, 98, 105.
- Hayreh, S.S. (1981). Posterior ischemic optic neuropathy. *Ophthalmologica*, 182, 29-41.
- Hollenborst, R.W., Wagener, H.P. (1950). Loss of vision after distant hemorrhage. *Prog Med Sci.*, 219, 209.
- Isayama, Y., Takashi, T. (1983). Posterior ischemic optic neuropathy; histopathology of the idiopathic form. *Ophthalmologica*, 187, 8-18.
- Isayama, Y., Takashi, T., Inove, M. (1983). Posterior ischemic optic neuropathy. *Ophthalmologica*, 187, 141-147.
- Johnson, M.V., Kincaid, M.C., Trobe, J.D. (1987). Bilateral retrobulbar optic nerve infarctions after blood loss and hypotension: A clinicopathological case study. *Ophthalmology*, 94, 1577-1584.
- Katz, D.M. (1994). Ischemic optic neuropathy after lumbar spine surgery. *Arch Ophthalmol*. 112, 925-931.
- Kay, M.C. (1991). Ischemic optic neuropathy. *Neurol Clin*, 9, 115-129.
- Kenkel, J.M., Lipschitz, A.H., Luby, M., Kallmeyer, I et al. (2004). Hemodynamic physiology and thermoregulation in liposuction. *Plast Reconstr Surg*, 114, 503-513.
- Lee, A.G. (1995). Reversible loss of vision due to posterior ischemic optic neuropathy. *Can J Ophthalmol*, 30, 327-329.
- Murphy, M.A. (2003). Bilateral posterior ischemic optic neuropathy after lumbar spine surgery. *Ophthalmology*, 110, 1454-1457.
- Murphy, M.A. (2003). Bilateral posterior ischemic optic neuropathy after lumbar spine surgery. *Ophthalmology*, 110, 1454-1457.
- Ranjana, S., Sanjiv, D. (1997). Postpartum hemorrhage producing acute ischemic optic neuropathy. *Asia-Oceania Journal of Obstetrics and Gynecology*, 19, 249-251.

- Remigio, D., Wertenbaker, C. (2000). Post-operative bilateral vision loss. *Surv. Ophthalmol.*, 44, 426-432.
- Sadaba, L.M., Garcia-Layana, A., Maldonado, M.J., Berian Jose M. (2006). Bilateral ischemic optic neuropathy after transurethral prostatic resection: a case report. *BMC Ophthalmol*, 6, 32.
- Shimo-Oku, M., Miyakazi, S. (1984). Acute anterior and posterior ischemic optic neuropathy. *Jpn J Ophthalmol*, 28, 159-170.
- Walkup, H.E., Murphy, J.D. (1952). Retinal ischemia with unilateral blindness: a complication occurring during pulmonary resection in the prone position. Report of two cases. *J Thorac Cardiovasc Surg*, 23, 174-175.
- Waybright, E.A., Selhorst, J.B., Combs, J. (1982). Anterior ischemic optic neuropathy with internal carotid artery occlusion carotid artery occlusion Subclavian steal syndrome. *Am J Ophthalmol*, 93, 42-47.

© 2012 Pedro-Egbe & Awoyesuku; This is an Open Access article distributed under the terms of the Creative Commons Attribution License (<http://creativecommons.org/licenses/by/3.0>), which permits unrestricted use, distribution, and reproduction in any medium, provided the original work is properly cited.