

Three Consecutive Monthly Intravitreal Ranibizumab for Choroidal Neovascularization in Central Serous Chorioretinopathy: A Case Report

Kazim Erol¹, Esin Sogutlu Sari^{2*}, Arif Koytak³, A. Karaçor¹, D. T. Çoban¹, M. Bulut¹

¹Ophthalmology Department, Antalya Training and Research Hospital, Antalya, Turkey; ²Ophthalmology Department, Kartal Training and Research Hospital, Istanbul, Turkey; ³Ophthalmology Department, Bezmialem Vakif University, Istanbul, Turkey.
Email: *dresinsogutlu@gmail.com

Received March 19th, 2012; revised April 25th, 2012; accepted May 8th, 2012

ABSTRACT

Purpose: The authors report the result of three consecutive monthly intravitreal ranibizumab injection for choroidal neovascularization (CNV) after bevacizumab injection for chronic central serous chorioretinopathy (CSR). **Methods:** A 48-year-old man with chronic CSR was treated with intravitreal single dose 2.5 mg bevacizumab. One year after CNV was occurred, and three consecutive monthly intravitreal ranibizumab injections were performed. **Results:** Four weeks later the first ranibizumab dose, best corrected visual acuity was improved 20/80 to 20/20 and remained stable within one year. **Conclusion:** Repeat intravitreal ranibizumab injection in CNV after bevacizumab injection for chronic CSR appeared to be an effective treatment option.

Keywords: Central Serous Chorioretinopathy; Choroidal Neovascularization; Ranibizumab

1. Introduction

Central serous chorioretinopathy (CSR) is common diseases of the posterior segment of the eye characterized by serous detachment of the neurosensory retina in the macula secondary to an idiopathic leakage in the outer blood-retinal barrier at the retinal pigment epithelium (RPE). Although visual distortions are usually mild and spontaneous recovery occurs within a few months, some patients with CSR have a poor visual acuity due to retinal pigment epithelium atrophy, persistent or recurrent pigment epithelial detachment, subretinal fluid and choroidal neovascularization (CNV) [1]. CNV secondary to CSR is an uncommon relation which has been also noted to complicate laser photocoagulation treatment due to the puncture of Bruch's membrane by laser burns and photodynamic therapy due to the RPE alterations and induces the release of vascular endothelial growth factor (VEGF) [2].

Different treatment options including photodynamic therapy with vertaporphin, laser photocoagulation, vitreoretinal submacular surgery and intravitreal anti VEGF agents (bevacizumab or ranibizumab) have been reported for the chronic and recurrent CSR with or without CNV. [2-5] We report the results of three consecutive monthly

intravitreal ranibizumab injection for CNV after bevacizumab injection for chronic CSR. To our knowledge there have been no previously reported cases of CNV after bevacizumab for the management of CSR.

2. Case Report

A 48-year-old man with a history of chronic ulcerative colitis had reported a 8-month history of blurry vision in his right eye and he had received prior medical treatment with acetazolamid. Metamorphopsia was noted and visual acuity was 20/40. RPE "sawtooth appearance" was present on optical coherence tomography (OCT) suggesting a chronic CSR (**Figure 1**). Treatment options were discussed and intravitreal bevacizumab (2.5 mg) injection was performed. Four weeks later best corrected visual acuity was improved to 20/20 and OCT revealed complete resolution of neurosensory serous detachment (**Figure 2**).

One year after the bevacizumab injection, the patient complained of decreased vision in his right eye for the past 2 weeks. Best corrected visual acuity was 20/80 and metamorphopsia was again noted. OCT imaging showed CNV with subretinal fluid (**Figure 3**). Treatment options were discussed three consecutive monthly intravitreal ranibizumab injection (0.5 mg) were performed. Four weeks later the last dose best corrected visual acuity was

*Corresponding author.

improved to 20/20 and OCT demonstrated the complete resolution of choroidal neovascular membrane and subretinal fluid (**Figure 4**). Follow-up examination at one year after the last ranibizumab injection vision remained stable on 20/20.

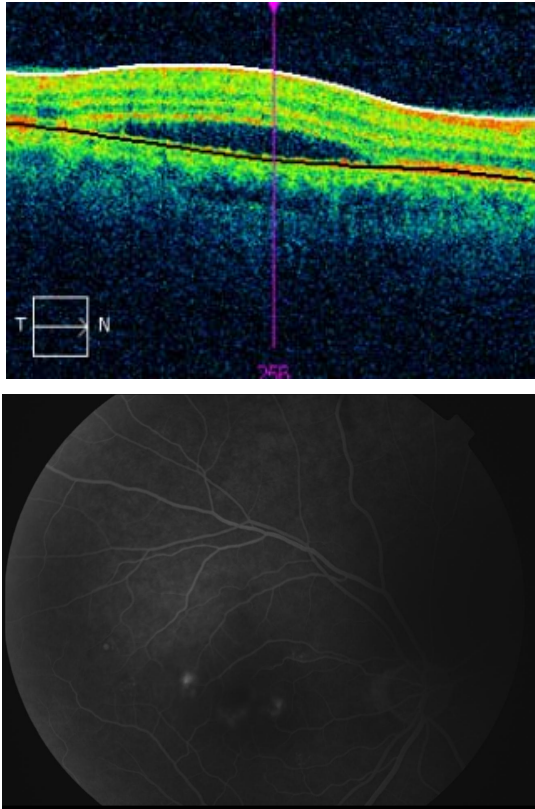


Figure 1. Baseline optical coherence tomography (OCT) showed serous detachment of the neurosensory retina with central macular thickness of 389 μm and “sawtooth appearance” of the retina pigment epithelium (RPE). Baseline fluorescein angiography (FA) showed RPE “window defect” with focal leakage of fluorescein.

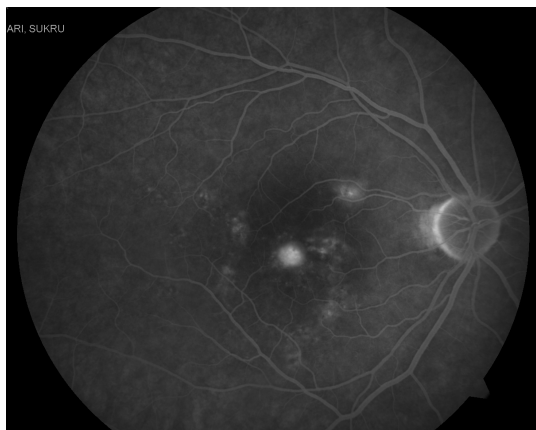


Figure 3. Fluorescein angiography (late frames) and optical coherence tomography demonstrating a subfoveal classic choroidal neovascular membrane with subretinal fluid.

3. Discussion

Chronic CSR which also known as diffuse retinal epitheliopathy characterised by persistent or recurrent serous retinal detachment with widespread pigmentary changes, decompensation of the RPE, multifocal or diffuse RPE alteration, increased permeability of the choroidal vessels. The growth of pathological blood vessels in the macular area secondary to CSR which is the reason of an overexpression of VEGF could appear either spontaneously or after laser and photodynamic treatment. Currently, anti-VEGF agents has been widely used in the treatment of CNV and also in proliferative diabetic retinopathy, and macular edema due to the cataract surgery, diabetes or retinal vein occlusion [6-8]. In recent years, studies demonstrated that VEGF antibodies could reduce choroidal hyperpermeability and choriocapillaris ischaemia associated with CSR [9]. In the current case report we shown the results of three consecutive monthly intravitreal ranibizumab injection for CNV after bevacizumab for chronic CSR.

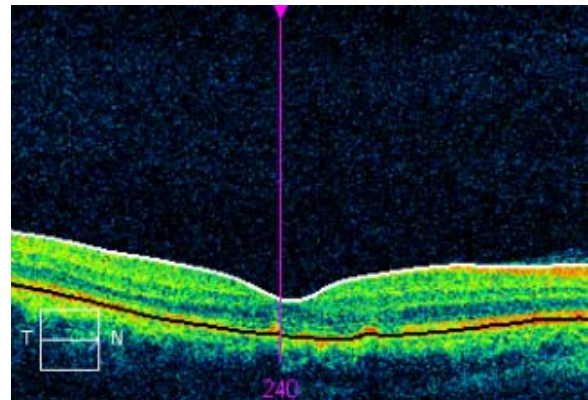
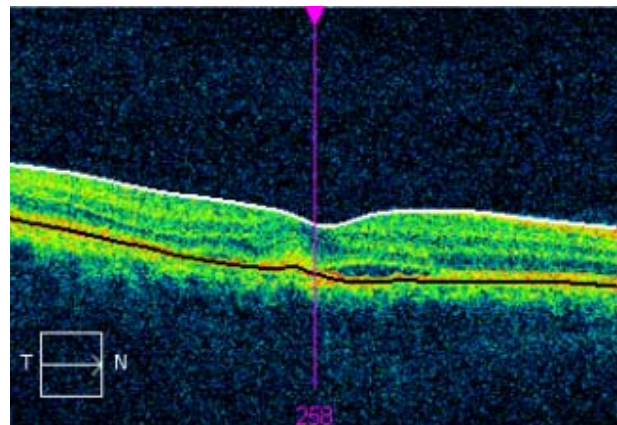


Figure 2. Optical coherence tomography demonstrated the complete resolution of neurosensory serous detachment with central macular thickness of 223 μm .



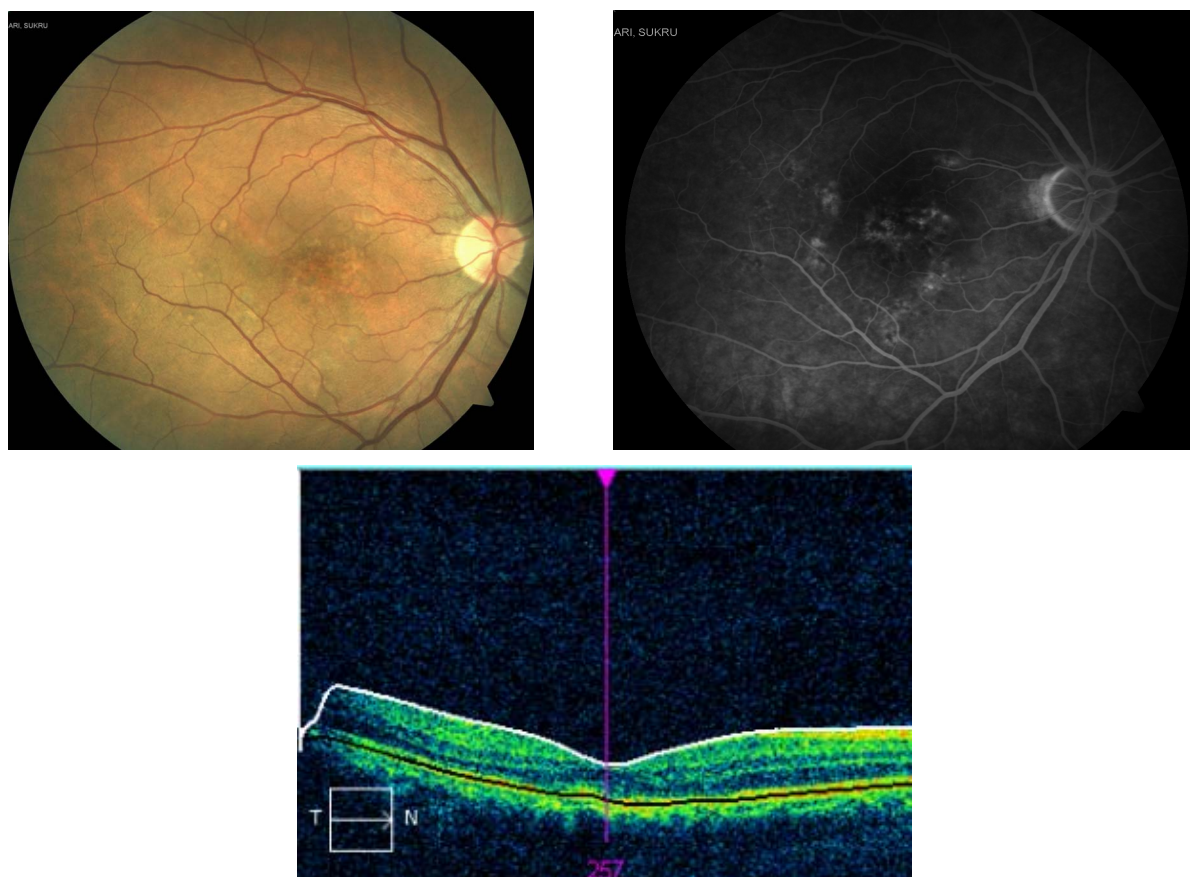


Figure 4. Clinical color photograph, fluorescein angiography (late phases) and optical coherence tomography demonstrating complete resolution of CNV and subretinal fluid.

In our case, chronic CSR was successfully treated with 2.5 mg of single dose intravitreal bevacizumab injection. However CNV occurred one year after the bevacizumab, then we decided to try repeat injection of another VEGF antibody ranibizumab for the management of CNV. Four weeks later, subretinal fluid and neovascular membrane was completely resolved and the vision improved to 20/20 and remained stable within one year. Both ranibizumab and bevacizumab, which are derived from the same parent molecule, inhibit all isoforms of VEGF. However, molecular and pharmacologic properties of these agents differ in several aspects. In an experimental animal model [10], ranibizumab has been shown to penetrate the choroid rapidly after an intravitreal injection. Bevacizumab is a three times larger molecule. Investigations, however, have proven the presence of bevacizumab throughout the neural retina, in the subretinal space and choriocapillaris within 24 hours of intravitreal injection.

Although CNV may complicate the natural history of CSR, in this case 2.5 mg single dose of bevacizumab did not prevent the developing CNV secondary to CSR. In 2008, Wang *et al.* [11] reported that subretinal granular deposits from the phagocytosis photoreceptor segment,

accumulating after retinal detachment could prevent the anti-VEGF treatment working in chronic CSR. Accordingly, Schaal *et al.* hypothesized that VEGF expression might be higher in patients with chronic CSR compared to patients with wet age-related macular degeneration (AMD) because affected areas are often multiple and widespread and not limited to the central part of the retina like in AMD and consequently might require higher doses of anti-VEGFs [12]. The same investigator reported that 50% of the cases demonstrated a complete resolution of subretinal fluid after treatment with 2.5 mg bevacizumab [12].

More recently, Kaiser *et al.* [13], shown that ranibizumab with a fixed 12-month dosing regimen of 0.5 mg has a favorable safety and efficacy profiles in patients with subfoveal CNV unresponsive to pegaptanib and bevacizumab. They explained this superiority with the fact that ranibizumab has a lower molecular weight and higher affinity to VEGF-A, which theoretically implies that it could better penetrate the retina and access the choroidal neovascular complex more readily. In addition, Rosenfeld *et al.* [14] reported that multiple intravitreal ranibizumab at escalating doses ranging from 0.3 to 2.0

mg were well tolerated and biologically active in eyes with neovascular AMD within 5-months. Guided by this researches in this case we performed repeat intravitreal ranibizumab injection in CNV after bevacizumab injection for chronic CSR and it appeared to be an effective treatment option. Our experience in this case was unable to prove that bevacizumab 2.5 mg could prevent the development of CNV as a complication of chronic CSC. Also in this case, ranibizumab was not found superior to bevacizumab in the treatment of the disease itself and in the prevention of its complications. However, we can hypothesize that a single dose of anti-VEGF may remain insufficient for improving the natural course of the disease and multiple doses may be more effective as in wet AMD. Further comparative studies with larger series and longer follow-up periods are needed in order to achieve a definitive conclusion on the role of anti-VEGF agents in the management of CSR.

4. Acknowledgments

The authors indicate no government or non-government financial support.

REFERENCES

- [1] R. H. Loo, I. U. Scott, H. W. Flynn Jr., J. D. Gass, T. G. Murray, M. L. Lewis, P. J. Rosenfeld and W. E. Smiddy, "Factors Associated with Reduced Visual Acuity during Long-Term Follow-Up of Patients with Idiopathic Central Serous Chorioretinopathy," *Retina*, Vol. 22, No. 1, 2002, pp. 19-24 [doi:10.1097/IAE.0b013e318134eccc](https://doi.org/10.1097/IAE.0b013e318134eccc)
- [2] H. Matsunaga, K. Nangoh, M. Uyama, H. Nanbu, Y. Fujiseki and K. Takahashi, "Occurrence of Choroidal Neovascularization Following Photocoagulation Treatment for Central Serous Retinopathy," *Nihon Ganka Gakkai Zasshi*, Vol. 99, 1995, pp. 460-468.
- [3] W. M. Chan, T. Y. Lai, D. T. Liu and D. S. Lam, "Intravitreal Bevacizumab (Avastin) for Choroidal Neovascularization Secondary to Central Serous Chorioretinopathy, Secondary to Punctate Inner Choroidopathy, or of Idiopathic Origin," *American Journal of Ophthalmology*, Vol. 143, No. 6, 2007, pp. 977-983. [doi:10.1016/j.ajo.2007.02.039](https://doi.org/10.1016/j.ajo.2007.02.039)
- [4] B. A. Cooper and M. A. Thomas, "Submacular Surgery to Remove Choroidal Neovascularization Associated with Central Serous Chorioretinopathy," *American Journal of Ophthalmology*, Vol. 130, No. 2, 2000, pp. 187-191 [doi:10.1016/S0002-9394\(00\)00395-0](https://doi.org/10.1016/S0002-9394(00)00395-0)
- [5] A. Koytak, K. Erol, E. Coskun, N. Asik, H. Oztürk, Y. Ozertürk, "Fluorescein Angiography-Guided Photodynamic Therapy with Half-Dose Verteporfin for Chronic Central Serous Chorioretinopathy," *Retina*, Vol. 30, No. 10, 2010, pp. 1698-1703. [doi:10.1097/IAE.0b013e3181da4354](https://doi.org/10.1097/IAE.0b013e3181da4354)
- [6] J. F. Arevalo, R. A. Garcia-Amaris, J. A. Roca, *et al.*, "Primary Intravitreal Bevacizumab for the Management of Pseudophakic Cystoid Macular Edema Pilot Study of the Pan-American Collaborative Retina Study Group," *Journal of Cataract & Refractive Surgery*, Vol. 33, No. 12, 2007, pp. 2098-2105. [doi:10.1016/j.jcrs.2007.07.046](https://doi.org/10.1016/j.jcrs.2007.07.046)
- [7] D. Iturralde, R. F. Spaide, C. B. Meyerle, J. M. Klancnik, L. A. Yannuzzi, Y. L. Fisher, J. Sorenson, J. S. Slakter, K. B. Freund, M. Cooney and H. F. Fine, "Intravitreal Bevacizumab (Avastin) Treatment of Macular Edema in Central Retinal Vein Occlusion: A Short-Term Study," *Retina*, Vol. 26, No. 3, 2006, pp. 279-284. [doi:10.1097/00006982-200603000-00005](https://doi.org/10.1097/00006982-200603000-00005)
- [8] D. Kook, A. Wolf, T. Kreutzer, A. Neubauer, R. Strauss, M. Ulbig, A. Kampik and C. Haritoglou, "Long-Term Effect of Intravitreal Bevacizumab (Avastin) in Patients with Chronic Diffuse Diabetic Macular Edema," *Retina*, Vol. 28, No. 8, 2008, pp. 1053-1060. [doi:10.1097/IAE.0b013e318176de48](https://doi.org/10.1097/IAE.0b013e318176de48)
- [9] S. J. Lim, M. I. Roh and O. W. Kwon, "Intravitreal Bevacizumab Injection for Central Serous Chorioretinopathy," *Retina*, Vol. 30, No. 1, 2010, pp. 100-106. [doi:10.1097/IAE.0b013e3181bcf0b4](https://doi.org/10.1097/IAE.0b013e3181bcf0b4)
- [10] J. Gaudreault, D. Fei, J. C. Beyer, A. Ryan, L. Rangell, V. Shiu, L. A. Damico, "Pharmacokinetics and Retinal Distribution of Ranibizumab, a Humanized Antibody Fragment Directed against VEGF-A, Following Intravitreal Administration in Rabbits," *Retina*, Vol. 27, No. 9, 2007, pp. 1260-1266. [doi:10.1097/IAE.0b013e318134eccc](https://doi.org/10.1097/IAE.0b013e318134eccc)
- [11] M. Wang, I. C. Munch, P. W. Hasler, C. Prunte and M. Larsen, "Central Serous Chorioretinopathy," *Acta Ophthalmologica*, Vol. 86, No. 2, 2008, pp. 126-145. [doi:10.1111/j.1600-0420.2007.00889.x](https://doi.org/10.1111/j.1600-0420.2007.00889.x)
- [12] K. B. Schaal, A. E. Hoeh, A. Scheuerle, F. Schuett and S. Dithmar, "Intravitreal Bevacizumab for Treatment of Chronic Central Serous Chorioretinopathy," *European Journal of Ophthalmology*, Vol. 19, No. 4, 2009, pp. 613-617.
- [13] R. S. Kaiser, O. P. Gupta, C. D. Regillo, A. C. Ho, M. S. Fineman, J. F. Vander, J. A. McNamara and G. C. Brown, "Ranibizumab for Eyes Previously Treated with Pegaptanib or Bevacizumab without Clinical Response," *Ophthalmic Surgery, Lasers and Imaging*, Vol. 43, No. 1, 2012, pp. 13-19.
- [14] P. J. Rosenfeld, J. S. Heier, G. Hantsbarger and N. Shams, "Tolerability and Efficacy of Multiple Escalating Doses of Ranibizumab (Lucentis) for Neovascular Age-Related Macular Degeneration," *Ophthalmology*, Vol. 113, No. 4, 2006, pp. 623-632. [doi:10.1016/j.ophtha.2006.01.027](https://doi.org/10.1016/j.ophtha.2006.01.027)