



Interposition of dartos flaps to prevent fistula after tubularized incised-plate repair of hypospadias

Ehab R. Elsayed, Abdellatif M. Zayed, Diab El Sayed & Mahmoud El Adl

To cite this article: Ehab R. Elsayed, Abdellatif M. Zayed, Diab El Sayed & Mahmoud El Adl (2011) Interposition of dartos flaps to prevent fistula after tubularized incised-plate repair of hypospadias, Arab Journal of Urology, 9:2, 123-126, DOI: [10.1016/j.aju.2011.06.007](https://doi.org/10.1016/j.aju.2011.06.007)

To link to this article: <https://doi.org/10.1016/j.aju.2011.06.007>



© 2011 Arab Association of Urology



Published online: 05 Apr 2019.



Submit your article to this journal [↗](#)



Article views: 199



View related articles [↗](#)



Arab Journal of Urology
(Official Journal of the Arab Association of Urology)

www.sciencedirect.com



PEDIATRIC UROLOGY

ORIGINAL ARTICLE

Interposition of dartos flaps to prevent fistula after tubularized incised-plate repair of hypospadias

Ehab R. Elsayed *, Abdellatif M. Zayed, Diab El Sayed, Mahmoud El Adl

Department of Urology, Faculty of Medicine, Zagazig University, Zagazig, Egypt

Received 13 April 2011, Received in revised form 12 June 2011, Accepted 27 June 2011

Available online 9 September 2011

KEYWORDS

Hypospadias;
Dartos flap;
Tubularized incised plate;
Fistula

ABBREVIATION

TIP, tubularized incised-plate

Abstract Objective: To evaluate the effect of urethral coverage by a single- or double-layered dorsal dartos flap after tubularized incised-plate (TIP) repair of hypospadias on fistula formation.

Patients and methods: In this retrospective study we evaluated sequential patients with hypospadias who underwent TIP urethroplasty with a dorsal dartos interpositional flap between April 2008 and December 2009. We reviewed their medical records for the site of hypospadias, previous hypospadias repair, single- or double-layered dartos flap and postoperative complications. The patients were divided into two groups; in group A the urethra was covered by a single layer of dartos fascia, and in group B the urethra was covered by double layers of dartos flap.

Results: Of 91 patients who opted for hypospadias repair during the time of the study, 62 had a TIP urethroplasty with a dorsal dartos flap; of these 62, three did not fulfil the requirement of the minimum follow-up, so 59 were eligible for the study (32 in group A and 27 in group B). Preoperative clinical data were comparable in both groups. At a mean of 12.2 months of follow-up, there was no reported fistula in group B, while two patients in group A developed a urethrocutaneous fistula ($P = 0.19$). Meatal stenosis occurred in two patients in group A and one in group B ($P = 0.66$).

Conclusion: There was no significant difference in subsequent urethrocutaneous fistula between a double-layered dorsal dartos flap and single layer for covering the urethra as a part of TIP urethroplasty for repairing hypospadias.

© 2011 Arab Association of Urology. Production and hosting by Elsevier B.V. All rights reserved.

* Corresponding author. Tel.: +20 146044499.

E-mail addresses: dr_ihabraafat@yahoo.com (E.R. Elsayed), mzayed1919@yahoo.com (A.M. Zayed), drdiab@yahoo.com (D. El Sayed), maladl@yahoo.com (M. El Adl).

2090-598X © 2011 Arab Association of Urology. Production and hosting by Elsevier B.V. All rights reserved.

Peer review under responsibility of Arab Association of Urology.
doi:10.1016/j.aju.2011.06.007

Introduction

In the last decades several new techniques to correct hypospadias have been developed but no single technique has been free of complications. The most common and annoying



Production and hosting by Elsevier

complication is urethrocutaneous fistula. To minimize the fistula rate, several procedures have been described, i.e. tunica vaginalis used as a blanket to wrap the urethra [1], or spongy tissue as an intermediate layer in urethral coverage [2], and a two-layer closure of the neourethra in conjunction with a vascularized dartos flap [3]. Retik et al. [4] used a dorsal dartos flap to wrap the neourethra after a meatal-based flap hypospadias repair.

Lastly, we and several others [5–7] have covered the neourethra by two layers of dorsal dartos flap as a safeguard to avoid fistula formation. In the present study we aimed to compare the outcomes of urethral coverage by a double-layered dorsal dartos flap vs. a single layer of dartos flap in tubularized incised-plate (TIP) urethroplasty to evaluate the influence of double layers of dorsal dartos flap in avoiding postoperative urethrocutaneous fistula.

Patients and methods

We retrospectively reviewed the medical records of sequential patients with hypospadias who were operated between April 2008 and December 2009. Those patients managed by TIP urethroplasty with a dorsal dartos interpositional flap were the subject of the study. According to the policy of our university ethical committee, patients' consent to participate in retrospective studies is not needed. The operation began by placing a stay suture in the glans penis for traction. The penis was injected with 1:200,000 adrenaline at the incision sites before degloving of the penile shaft. The penile skin was degloved and an artificial erection induced to assess residual curvature. Two longitudinal incisions were made along the visible junction of the glans and the urethral plate. The glans wings were mobilized laterally. Next, the urethral plate was incised along the midline from the meatus to its distal tip, extending deeply to near the corpora cavernosa. A 6–8 F Silastic stent was then passed into the bladder and the urethral plate was tubularized with running subepithelial 6/0 polyglactin sutures up to the mid-glans level to leave an oval distal urethral opening. We divided the patients into two groups; in group A, the urethra was covered by a single-layered dorsal dartos fascia, and in group B the urethra was covered by two layers of dorsal dartos fascia.

For all patients, the dartos flap was harvested from the preputial and dorsal penile shaft. For group A the flap was transposed to the ventral aspect in a button-hole manner and fixed over the neourethra. For group B the neourethra was covered by double dartos flaps in an attempt to avoid fistula formation. The dorsal dartos flap was divided in the midline into right and

left halves (Fig. 1). The right half was turned on the right side to the ventral aspect and the left half was turned on the left side to the ventral aspect. Both flap strips were overlapped and fanned out to reduce the bulk of the flap. Each flap strip was sutured to the contralateral recess of the raised glanular wing around the neomeatus, and to the corpora cavernosa over the neourethra. For all patients, the glanular wings were sutured over the flaps to create a conical glans with vertically orientated meatus. During surgery all patients received intravenous antibiotics (ampicillin and gentamicin), both then maintained for 3 days. A dressing was applied and changed 72 h after surgery, with subsequent dressings applied every other day. The urethral stent (6–8 F, according to the urethral diameter and patient age) was kept in place for 5–7 days after surgery.

The patients were followed up weekly for 1 month and then monthly for 6 months, with a physical examination of the penis and neomeatus at each visit. Voiding patterns (stream force and calibre) were assessed. The minimum follow-up was 3 months and the outcome was evaluated for fistula formation and urethral stricture. Data were analysed using Student's *t*-test to compare means, with $P < 0.05$ considered to indicate significance.

Results

In all, 59 patients were eligible for the study (32 in group A and 27 in group B); the mean (SD, range) age of the patients was 3.7 (1.2, 2–8) years. Forty-one (70%) patients had distal penile hypospadias, 10 (17%) had mid-shaft and eight (14%) had proximal hypospadias. Eleven patients (19%) were already circumcised and in eight (14%) previous attempted repairs had failed. Both groups were comparable, with no statistical difference in age, preoperative site of urethral meatus, previous hypospadias repair, and circumcision (Table 1). At a mean (SD) of 12.2 (3.8) months of follow-up there was no reported fistula in all 27 children in group B, but two of 32 in group A had a urethrocutaneous fistula at the site of hypospadiac opening in proximal penile urethra (one re-do repair and one primary). Although there were more fistulae in group A this was not statistically significant ($P = 0.19$). The fistula was corrected surgically at 6 months after initial surgery. Meatal stenosis occurred in two patients in group A and one in group B ($P = 0.66$), and was treated by meototomy.

Discussion

Most paediatric urologists prefer the TIP urethroplasty for repairing hypospadias [8]. Although this procedure has been

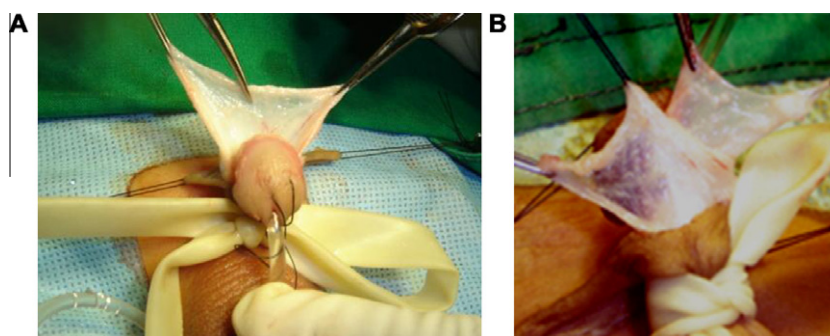


Figure 1 (A and B) The dorsal dartos flap was divided in the midline into right and left halves.

Table 1 The preoperative clinical characteristics of the two groups.

Variable	Group A	Group B	P
Patient number	32	27	
Mean (SD) age, years	3.9 (1.3)	3.6 (1.1)	0.27
Recurrence, <i>n</i>	5	3	0.62
Site of urethral opening, <i>n</i> :			0.11
Distal penile	21	20	
Mid-shaft	4	6	
Proximal penile	7	1	
Circumcision	6	5	0.98

reported by several authors [9–12] to be excellent for hypospadias repair, regardless of the site of the meatus and configuration of the urethral plate, it is not free of complications particularly urethrocutaneous fistula and meatal stenosis [13,14]. Some authors [5–7] considered that the two-layered interpositional flap is warranted to avoid fistula formation. Several factors, such as suture material, infection, previous operations, catheterization and surgical skill, can affect the outcome significantly. To avoid the occurrence of fistula, various procedures have been developed, e.g. in-turning all epithelium and using uninterrupted subepithelial sutures can minimize fistula formation [4]. In a study of 172 patients with hypospadias who had a TIP repair, fistula was detected in 0.7% of those who had the TIP with interposition of double dorsal flaps, in 29.4% of those who had a flap-less TIP with no interposition of covering flap, and in 26% who underwent TIP with single dartos flap covering [15]. However, Snodgrass et al. [16] reported that there was no difference in fistula rates between patients with and without a barrier flap. Also, Elbakry [17] argued that the dartos flap interposition might hinder tension-free closure of the glans flaps, and increases the risk of glanular dehiscence. The findings of Snodgrass et al. [16] and Elbakry [17] indicated that dartos covering of the neourethra is not an absolute requirement to avoid fistula formation after TIP hypospadias repair, and perfection of all other technical steps is mandatory. For several years we used to cover the urethra with a single layer of dorsal dartos fascia, and later we changed, covering the neourethra with a double-layered dorsal dartos fascia, in an attempt to minimize fistula formation. In the present retrospective comparative study, we could not detect a statistically significant difference between the groups of patients in the rate of fistula formation. The drawback of the double dartos flap is that it restrains a tension-free closure of the glans, but Abolyosr [7] tried to overcome this drawback by wide separation of the glanular wings, and just approximating the edges. In addition, in the present study we fanned out the flap strips over the neourethra to reduce its bulk. There was no wound dehiscence in either group. Elbakry [17] argued that the adhesions between both sides of the incised plate can result in meatal stenosis and subsequent fistula formation, and he recommended regular urethral dilatation after surgery, while Lorenzo and Snodgrass [18] denied the need for regular urethral dilatation, depending instead on the force of the urinary stream to separate the two sides of the raw area. In the present study, regular postoperative dilatation was not used. Three patients (5%) had meatal stenosis that was treated by meototomy. The meatal stenosis

rate could be reduced by keeping the meatus one stitch short of complete closure [11]. Hammouda et al. [19], in a series of 48 patients, reported that only 69% of their patients had a normal peak flow rate at an intermediate follow-up. In the present retrospective study, we depended on a patient history and observation of the urinary stream force and calibre during the relatively short follow-up period. However, Nuininga et al. [20] considered that the final outcome of hypospadias surgery can only be evaluated once the patient has reached adulthood.

The limitations of the present study were the relatively few patients and the common limitations of retrospective studies. Although no fistula was detected in group B patients, the difference between the groups was statistically insignificant. Similar findings were reported in another study of 96 patients who underwent TIP repair, with double dartos flap interposition in 42 and single dartos flap interposition in 54; a fistula was detected in two of the latter [5].

In conclusion, in this retrospective small study, there was no statistically significant difference in urethrocutaneous fistula rate between a double-layered dartos flap and a single layer for covering the neourethra as a part of TIP hypospadias repair. Prospective randomized clinical trials with many patients are required to confirm or refute this conclusion.

References

- [1] Snow BW, Cartwright PO, Unger K. Tunica vaginalis blanket wrap to prevent urethrocutaneous fistula. *J Urol* 1995;153:472–3.
- [2] Gamal WM, Zaki M, Rashid A, Mostafa M, Abouzeid AM. Tubularized incised-plate (TIP) repair augmented by spongioplasty for distal and midpenile hypospadias. *UIJ* 2009. doi:10.3834/uij.1944-5784.2009.06.13.
- [3] Cheng EY, Vemulapalli SN, Kropp BP, Pope JCIV, Furness PD, Kaplan WE, et al. Snodgrass hypospadias repair with vascularized dartos flap. The perfect repair for virgin cases of hypospadias? *J Urol* 2002;168:1723–6.
- [4] Retik AB, Mandell J, Bauer SB, Atala A. Meatal based hypospadias repair with the use of a dorsal subcutaneous flap to prevent urethrocutaneous fistula. *J Urol* 1994;152:1229–31.
- [5] Kamal BA. Double dartos flaps in tubularized incised plate hypospadias repair. *Urology* 2005;66:1095–8.
- [6] Zayed AM. Double dartos interposition flaps in Snodgrass hypospadias repair. *Arab J Urol* 2006;4:28–31.
- [7] Abolyosr A. Snodgrass hypospadias repair with onlay overlapping double-layered dorsal dartos flap without urethrocutaneous fistula. Experience of 156 cases. *J Pediatr Urol* 2010;6:403–7.
- [8] Cook A, Khoury AE, Neville C, Bagli DJ, Farahat WA, Pippi Salle JL. A multicenter evaluation of technical preferences for primary hypospadias repair. *J Urol* 2005;174:2354–7.
- [9] Borer SG, Bauer SB, Peters CA, Diamond DA, Atala A, Cilento Jr BG, Retik AB. Tubularized incised plate urethroplasty. expanded use in primary and repeat surgery for hypospadias. *J Urol* 2001;165:581–5.
- [10] Shahan AM, Khalil SA, El-Bendary LA, Abdellatif A, Shahan TM. Does tubularized incised plate urethroplasty fit primary and repeat shaft hypospadias repair? *African J Urol* 2002;8:24–31.
- [11] Guralnick ML, Al-Shammari A, Williot PE, Leonard MP. Outcome of hypospadias repair using the tubularized, incised plate urethroplasty. *Can J Urol* 2000;7:986–91.
- [12] Sozubir S, Snodgrass W. A new algorithm for primary hypospadias repair based on tip urethroplasty. *J Pediatr Surg* 2003;38:1157–61.

- [13] Nguyen MT, Snodgrass WT, Zaontz MR. Effect of urethral plate characteristics on tubularized incised plate urethroplasty. *J Urol* 2004;**171**:1260–2.
- [14] Snodgrass WT, Lorenzo A. Tubularized incised-plate urethroplasty for proximal hypospadias. *BJU Int* 2002;**89**:90–3.
- [15] Yigiter M, Yildiz A, Oral A, Salman AB. A comparative study to evaluate the effect of double dartos flaps in primary hypospadias repair: no fistula anymore. *Int Urol Nephrol* 2010;**42**:985–90.
- [16] Snodgrass WT, Bush N, Cost N. Tubularized incised plate hypospadias repair for distal hypospadias. *J Pediatr Urol* 2010;**6**:408–13.
- [17] Elbakry A. Tubularized-incised urethral plate urethroplasty: is regular dilatation necessary for success? *BJU Int* 1999;**84**:683–8.
- [18] Lorenzo AJ, Snodgrass WT. Regular dilatation is unnecessary after tubularized incised-plate hypospadias repair. *BJU Int* 2002;**89**:94–7.
- [19] Hammouda HM, El-Ghoneimi A, Bagli DJ, McLorie GA, Khoury AE. Tubularized incised plate repair: functional outcome after intermediate followup. *J Urol* 2003;**169**:331–3.
- [20] Nuininga JE, De Gier RP, Verschuren R, Fietz WF. Long-term outcome of different types of 1-stage hypospadias repair. *J Urol* 2005;**174**:1544–8.