

Diagnostic Difficulty of Breast Lump- Revealed a Rare Entity

Pandiaraja^{1*}

¹SRM Medical College, Potheri, Kancheepuram, 603203, India.

Author's contribution

The sole author designed, analyzed and interpreted and prepared the manuscript.

Article Information

DOI: 10.9734/JAMPS/2015/20643

Editor(s):

- (1) Divya Kesanakurti, Department of Cancer Biology and Pharmacology, University of Illinois College of Medicine, USA.
(2) Franciszek Burdan, Experimental Teratology Unit, Human Anatomy Department, Medical University of Lublin, Poland.

Reviewers:

- (1) Anonymous, Erzincan University, Turkey.
(2) Abrao Rapoport, Sao Paulo University, Brazil.

Complete Peer review History: <http://sciencedomain.org/review-history/11477>

Case Study

Received 1st August 2015
Accepted 31st August 2015
Published 19th September 2015

ABSTRACT

Lipoma is a benign soft tissue tumor of adipose tissue. Most of the time lipoma is diagnosed based on clinical features. Histopathological confirmation needed in certain cases. There are many subtypes of lipoma. One of the rare variant of lipoma is chondrolipoma. This is a case report of 58 years old female presented with lump in the right breast which has a diagnostic difficulty. Later it was diagnosed as chondrolipoma of breast. This case is reported due to its rarity in breast.

Keywords: Chondrolipoma; adipose tissue; benign mesenchymal tumor; hyaline cartilage; excision and biopsy.

1. INTRODUCTION

Lipoma can present as adenolipoma, angioliipoma, chondroid lipoma, neurolipoma, fibrolipoma, pleomorphic lipoma. Chondrolipoma is a benign mesenchymal tumor of adipose tissue which is composed of both adipose tissue

and true hyaline cartilage [1]. It can occur in the breast. Chondrolipoma of breast can mimic like carcinoma breast due to its hard consistency in clinical examination and micro calcification on mammogram. So it can create a diagnostic difficulty when it occurs in the breast.

*Corresponding author: E-mail: dr.pandiaraja@gmail.com;

2. CASE REPORT

A 58 years old female patient admitted with complaints of lump in the right breast for 11 month duration, which was gradual, progressive. No history of pain in the lump or nipple discharge. No history of any constitutional symptoms. On examination a single lump of 4x3 cm present in the lower and outer quadrant of right breast. Lump is hard in consistency, mobile along with breast tissue. Mass is not attached to underlying surface or pectoral muscle. Nipple areolar complex found to be free. Contra lateral breast and both axilla found to be free. Clinically patient was diagnosed as carcinoma breast.

Sonomammogram showed a lump of 4x3cm present in right lower and outer quadrant with pleomorphic micro calcifications with BIRADS IV (Fig. 1), suggested histopathological examination. A fine needle aspiration showed no evidence of malignancy. Image guided trucut biopsy shows no evidence of malignancy, except fat globule. Other investigations found to be normal. As the mass was less than 4 cm with negative core needle biopsy, planned for excision biopsy. Excision biopsy showed a tumor of 4x3 cm present in the right lower and outer quadrant. Mass was not adherent to underlying structures. Cut sections showed yellowish fatty tissue with multiple small calcifications (Fig. 2). Histopathological examination showed mature adipose tissue with hyaline cartilage. There were areas of micro calcification in the specimen (Fig. 3).

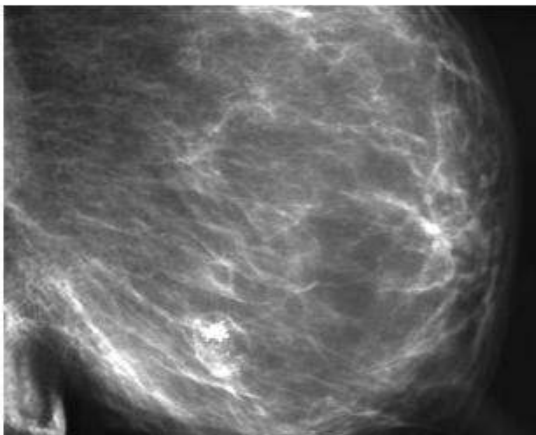


Fig. 1. Sonomammogram showed a lump of 4x3 cm present in right lower and outer quadrant with pleomorphic micro calcifications with BIRADS IV

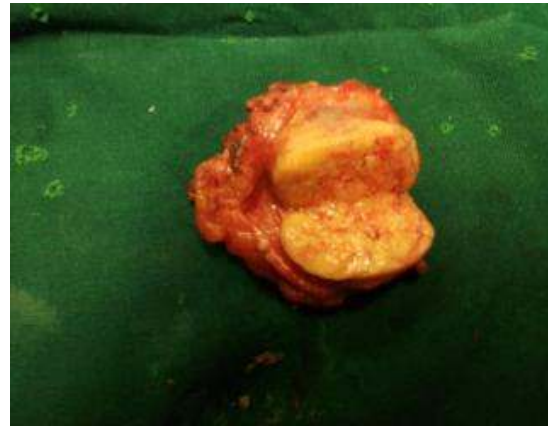


Fig. 2. Cut sections of breast lesion showed yellowish fatty tissue with multiple small calcifications

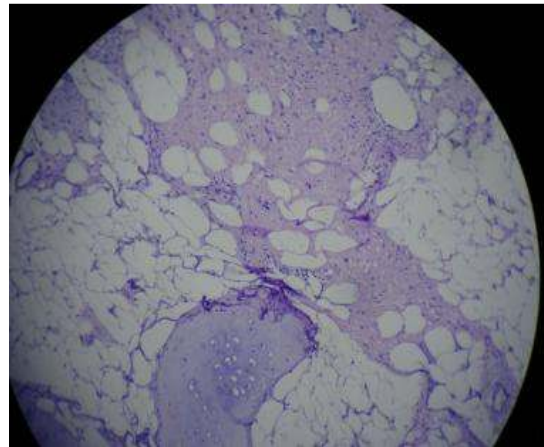


Fig. 3. Histopathological examination showed mature adipose tissue with hyaline cartilage. There were areas of micro calcification in the specimen

3. DISCUSSION

Chondrolipoma is a benign mesenchymal tumor of adipose tissue, which composed of adipose tissue and true mesenchymal hyaline cartilage [1]. Chondrolipoma is considered as cartilaginous metaplasia of lipoma. Most of the time etiology is unknown. But proposed hypothesis is differentiation of pluripotent mesenchymal cells into both adipose and cartilage tissue. The trigger for dedifferentiation was either local trauma or ischemia. It can present in breast, extremities, tongue and other sites [2,3]. Both male and female are affected, but females are affected more compared to male.

Chondrolipoma breast most of the time was misdiagnosed due to its similarity with fibroadenoma [4]. Clinical features vary from palpable lump to giant breast mass. Sometimes it can be misdiagnosed as carcinoma due to its calcification on mammogram [5]. Preoperative diagnosis will be difficult due to its presentation.

Histopathological features of chondrolipoma are well capsulated tumor mass consisting of mature adipose tissue with hyaline cartilage [6]. It contains both chondroid and adipose tissue. Calcifications rarely occur in chondrolipoma. Our case was one of the case which reported with calcifications.

There are few differences with chondroid lipoma and chondrolipoma. Chondrolipoma contain true hyaline cartilage, whereas chondroid lipoma doesn't contain true hyaline cartilage [7].

Even though chondrolipoma has diagnostic difficulty like our case, the treatment modality was simple. Most of the time simple excision was treatment of choice in most of the cases [8]. But excision should include capsule of chondrolipoma. Most of the cases no recurrences occur after proper excision with capsule.

4. CONCLUSION

Chondrolipoma of breast is a rare entity. Most of the time it will be misdiagnosed either fibroadenoma or carcinoma breast, because it contains both features of fibroadenoma like mobile, firm mass as well as features of carcinoma like hard mass with calcification on mammogram. Pre operative diagnosis will be difficult because it will show fat cells. So image guided core needle biopsy or excision biopsy needed for proper diagnosis. Always consider chondrolipoma is one of the differential diagnoses for micro calcifications in the breast on mammogram.

CONSENT

All authors declare that 'written informed consent was obtained from the patient (or other approved parties) for publication of this case report and accompanying images.

ETHICAL APPROVAL

It is not applicable.

COMPETING INTERESTS

Author has declared that no competing interests exist.

REFERENCES

1. Tasić D, Pavlović M, Stanković D, Dimov I, Stanojević G, Dimov D. Ossifying chondrolipoma of the tongue. *Vojnosanit Pregl.* 2012;69(11):1009–12.
2. Ozer F, Bal N. A Rare Diagnosis in the neck during childhood: Congenital Chondrolipoma. *Turk Patoloji Derg;* 2014.
3. Ohtsuka H. Chondrolipoma of the popliteal fossa and Japanese reports. *J Dermatol.* 2006;33(3):202–6.
4. Banev SG, Filipovski VA. Chondrolipoma of the breast-case report and a review of literature. *Breast Edinb Scotl.* 2006;15(3):425–6.
5. Sudhamani S, Kiri V, Pandit A. Chondrolipoma of breast: A case report with the review of the literature. *J Sci Soc.* 2012;39(3):147.
6. Pitman KT, Bell D. Chondrolipoma of head and neck: Case report and review of literature. *Head Neck.* 2013;35(1):E18–20.
7. Jorwekar GJ, Baviskar PK, Sathe PM, Dandekar KN. Giant Chondroid Lipoma of breast. *Indian J Surg.* 2012;74(4):342–3.
8. Baric A, Jewell W, Chang CHJ, Damjanov I. Chondrolipoma of the breast. *Breast J.* 2005;11(3):212–3.

© 2015 Pandiaraja; This is an Open Access article distributed under the terms of the Creative Commons Attribution License (<http://creativecommons.org/licenses/by/4.0>), which permits unrestricted use, distribution, and reproduction in any medium, provided the original work is properly cited.

Peer-review history:
The peer review history for this paper can be accessed here:
<http://sciencedomain.org/review-history/11477>