

An Uncommon Cause of Antepartum Haemorrhage: A Case Study

**John Osaigbovoh Imaralu¹, Atinuke Olukemi Olaleye^{1*}, Adeola Ajose¹
and Kolawole Aramide²**

¹*Department of Obstetrics and Gynaecology, Babcock University Teaching Hospital, Ilishan-Remo, Nigeria.*

²*Department of Histopathology, Babcock University Teaching Hospital, Ilishan-Remo, Nigeria.*

Authors' contributions

This work was carried out in collaboration among all authors. Authors JOI and AOO assessed the patient clinically and performed the caesarean section. Author AA took the cervical tissue biopsy while author KA performed the histologic diagnosis. Authors JOI, AOO and AA wrote the initial draft of the manuscript. All authors read and approved the final manuscript.

Article Information

Editor(s):

(1) Dr. Charbell Miguel Haddad Kury, Professor, Department of Pediatrics and Biochemistry, Medicine School of Campos Dos Goytacazes, Universidade Federal do Rio de Janeiro, Brazil.

Reviewers:

(1) Magdy Abdelrahman Mohamed, Sohag University, Egypt.

(2) Sivalingam Nalliah, International Medical University, Malaysia.

Complete Peer review History: <http://www.sdiarticle3.com/review-history/50675>

Case Study

Received 29 May 2019
Accepted 11 August 2019
Published 16 August 2019

ABSTRACT

Aim: To highlight the potential for benign lesions of the cervix uteri to present in bizarre unexpected ways during late pregnancy and the need for cautious evaluation to ensure optimal treatment is given, especially when life-altering decisions need to be made.

Presentation of Case: We present here a literature review and a case of 25 year old primigravida with twin gestation and antepartum hemorrhage (APH) initially thought to be due to cervical cancer but which turned out to be caused by chronic cervicitis.

Discussion: Obstetric hemorrhage remains the commonest cause of maternal mortality and morbidity in Nigeria. The occurrence of APH portends grave risks to the fetus and mother. A high risk of prematurity exists when bleeding occurs before term; a further risk of caesarean hysterectomy exists when a diagnosis of cervical cancer is suspected in women with APH. Infective cervical lesions such as cervicitis have been reported as causes of antepartum hemorrhage, but they are not significant enough to determine or affect obstetric outcome. Chronic

*Corresponding author: Email: olaleyea@babcock.edu.ng, tinukeolaleye@gmail.com;

cervicitis presenting as heavy antepartum hemorrhage leading to preterm delivery is a rare occurrence.

Conclusion: Infective lesions of the cervix are important benign causes of antepartum hemorrhage; the ability of chronic cervicitis to mimic exophytic cervical cancer is a consequence of physiologic changes in pregnancy which should be considered during patient evaluation. Cautious patient assessment should be done to ensure optimal care is given without undue risk to the fetus or mother.

Keywords: Antepartum hemorrhage; caesarean section; cervicitis; hysterectomy; misdiagnosis.

1. INTRODUCTION

Obstetric haemorrhage remains the commonest cause of adverse maternal and perinatal outcomes in Nigeria and many developing countries. Antepartum haemorrhage (APH), is an obstetric emergency which is defined as bleeding from the genital tract after the age of viability, but before the delivery of the baby [1]. Although majority is due to placenta praevia and placental abruption, less common pathologies include cervical erosion, ectropion, genital tumors, vulvar varicosities, ruptured vasa previa, and heavy show. The cause of APH however remains undetermined in about half of the cases [1,2].

Antepartum haemorrhage carries a high risk of perinatal morbi-mortality, accounting for up to 25% of perinatal deaths [3,4]. This could be a direct result of the cause of bleeding as seen in placental abruption, or a consequence of prematurity following any cause of antepartum haemorrhage necessitating delivery [3]. Prematurity and low birth weight are major challenges posed by antepartum haemorrhage, with some survivors at risk of long-term neurocognitive deficits and physical disability such as cerebral palsy and mental retardation [1].

A diagnosis of cervical cancer is first made in pregnancy in approximately 1-3% of patients [5]. Cervical cancer has been reported as a well-known cause of antepartum haemorrhage. The difference between the management of antepartum haemorrhage due to cervical cancer and that from the foregoing lesions is that women with a diagnosis of cervical cancer have a high risk of caesarean hysterectomy. This risk is even higher in sub-Saharan regions like Nigeria where presentation with overt cervical cancer is the norm [6,7]. The acute life-threatening nature of antepartum haemorrhage and the paucity of emergency histological diagnostic services make

over-treatment and undue hysterectomy for benign lesions more likely in these settings. Cervical cancer in the developed world today is a rare occurrence as preventive programs on vaccination and screening for premalignant lesions have been widely embraced, leading to a near eradication of the condition [6]. Chronic cervicitis is a recognized differential diagnosis of cervical cancer. It is however uncommon as a cause of antepartum hemorrhage necessitating preterm delivery. There is a low incidence of local cervical pathology presenting as APH, and chronic cervicitis in particular rarely causes heavy bleeding that would require for intervention. We present here a literature review and a case of 25 year old primigravida with twin gestation and antepartum hemorrhage (APH) initially thought to be due to cervical cancer but which turned out on histology to be caused by chronic cervicitis.

2. PRESENTATION OF CASE

A 25 year old primigravida presented to the obstetrics emergency at 33 weeks of gestation with a five hour history of bleeding per vaginam, which was of insidious onset, but later became heavy and contained fresh blood with associated clots. There was no drainage of liquor and she could still perceive fetal movements. There were no previous warning haemorrhages, post coital bleeding, or bleeding from any other orifice. She had no history of recent pelvic instrumentation or abdominal trauma. Her last coital exposure was three weeks prior to onset of symptoms. She had never had any form of screening for cervical cancer.

She booked for antenatal care at our hospital at seven weeks gestational age. She had routine booking investigations done which were essentially normal. Ultrasound scanning done at 12 weeks gestation showed dichorionic, diamniotic twin gestation. She had regular antenatal visits and pregnancy remained

uneventful until 33 weeks gestation. Examination revealed tachycardia on admission (PR 110bpm), but blood pressure was normal (128/78 mmHg). The abdomen was uniformly enlarged, soft, and the uterus non-tender with 2 palpable contractions in 10 minutes. The symphysio-fundal height (SFH) was 39cm; multiple fetal poles were palpated with leading twin in longitudinal lie, cephalic presentation and fetal heart rate of 140bpm. Vaginal examination revealed a normal female external genitalia, vulva was smeared with altered blood, moderate active bleeding from the introitus, no vaginal lesions or laceration was seen but sterile speculum examination showed a bulky cervix with a cauliflower lesion on the ectocervix measuring about 4cm in its widest diameter which obscured the external os and exhibited contact bleeding (Fig. 1). A biopsy of the lesion was taken for histology and the vagina packed with gauze to be removed in 2 hours.

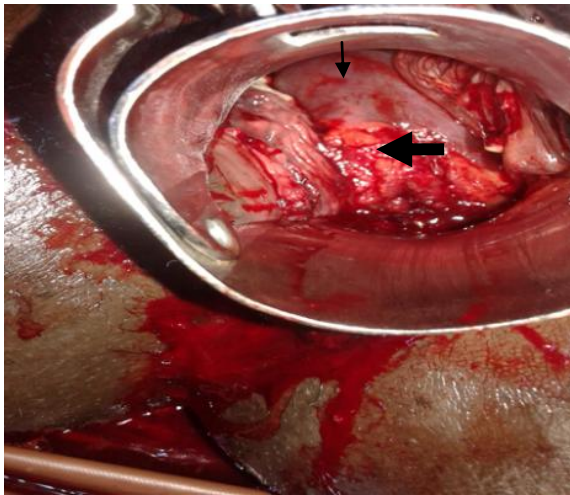


Fig. 1. Speculum view of the cervix (Thin arrow) with a cauliflower lesion on ectocervix (Thick arrow) and contact bleeding

Obstetric ultrasound scan revealed live twin fetuses with normally situated placentae and closed internal os. An assessment of APH due to suspected cervical cancer was made. Complete blood count revealed Hemoglobin concentration of 10.5g/dl, platelet count of $253 \times 10^9/L$ and white blood cell count of $10.2 \times 10^9/L$ with 86.9% granulocytosis. Electrolytes, urea, creatinine and clotting profile were within normal limits. Her blood group was O rhesus positive and two units of blood were cross matched.

She was administered crystalloids, analgesics, and Dexamethasone for fetal lung maturity.

Removal of the vaginal pack and inspection of the cervix 2 hours later showed continued bleeding and together with the clots an estimated loss of 400mls was made. The uterine contractions had increased at this time. Emergency lower segment caesarean section was done and intraoperative findings included centrally placed gravid uterus, twin foetuses both in longitudinal lie, cephalic presentation; T¹ – Female, Agar score- 5¹, 7⁵, Birth weight 2.02 kg; T² - Male, Agar score- 6¹, 8⁵, Birth weight 2.10 kg. Clear amniotic fluid was noted; the placentas were postero-lateral and fundal respectively and there was no retroplacental clot. She was then placed on oxytocin infusion, antibiotics, analgesics and intravenous fluids. Repeat vaginal examination in the early postoperative period revealed absence of bleeding from the ectocervix, a small necrotic lesion (1 cm) at about 11 O'clock position (one of the biopsied points) on the cervix with minimal contact bleeding, other parts of the cervix appeared grossly normal, only lochia from the uterus was noted. She made satisfactory progress and was discharged on the fifth post-operative day. Histology revealed chronic ulcerative cervicitis with moderate dysplastic changes, but no evidence of overt malignancy seen (Fig. 2). Her antibiotics were then reviewed and she was placed on Ceftriaxone, Secnidazole and Azithromycin. Speculum examinations done during follow up visits at two and six weeks postnatal revealed a grossly normal healthy looking cervix without contact bleeding. Both babies were doing well, and were being breastfed. She was then enrolled into the routine cervical screening program.

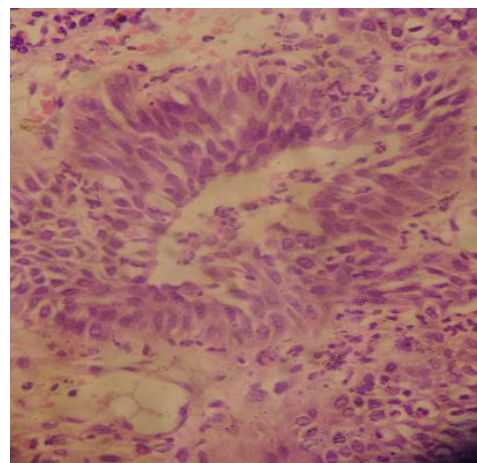


Fig. 2. Intraepithelial inflammatory cells and dysplasia of the glandular epithelial cells (x400 magnification)

3. DISCUSSION

Although antepartum haemorrhage has been reported to have a low incidence rate, its occurrence portends dire consequences for the mother and her fetus [3,4]. Early booking for antenatal care in this patient afforded us the opportunity to have baseline investigation results such as ultrasound scanning, which revealed a normal placenta location. Placenta praevia is a recognized cause of antepartum haemorrhage, and multiple pregnancy is a risk factor. However, the normal placenta location on ultrasound scanning and absence of warning hemorrhage in early pregnancy made placenta praevia unlikely.

Placental abruption complicates 2-5% of pregnancies [8] and is another close differential diagnosis because of the presence of painful uterine contractions. The absence of a history of hypertension or abdominal trauma and the finding of normal blood pressure with lack of proteinuria made this diagnosis unlikely. Other recognized risk factors or features of placental abruption such as history of smoking, substance abuse, dizziness or fainting spell were absent in this patient. The finding of a normal fetal heart tone also helped to rule out placental abruption, as it is often associated with fetal heart rate abnormalities and a high rate of fetal demise [9].

Bleeding from a cervical cancer lesion is a recognized cause of antepartum haemorrhage which has been reported in literature [10-13]. The findings from a large American study reveals that the rate of first diagnosis of cervical cancer is approximately equal in the three trimesters of pregnancy [12]. Evidence from other studies also back up this theory that the physiologic changes of pregnancy do not prevent or worsen the progression of the disease [14]. Women diagnosed with cervical cancer in pregnancy however have greater risk of hysterectomy [10,14]. Cervical cancer is the most common gynaecologic malignancy that complicates pregnancy and it has an incidence of 1/2200 [15].

Another important reason for considering cervical cancer as diagnosis is the fact that late presentation with advanced or even metastatic disease is a common finding in Nigeria and many sub Saharan African countries, where uptake of screening services is very low [6]. This condition has however been almost completely eradicated from developed countries because of early diagnosis and treatment of pre-malignant stages of the disease [11,15]. Pregnancy is not a contraindication to screening, as the

squamocolumnar junction becomes more accessible due to the inversion of the transformation zone from high levels of circulating oestrogen [11]. Caution is however required in interpreting smear results as the cervical glands and stroma undergo changes which lead to ectropion and resultant squamous metaplasia. This Arias-Stella reaction manifests as enlarged cells with hypervacuolated cytoplasm and nuclear atypia. Degenerated decidual or trophoblastic cells can also shed from the endometrium and mimic high grade Squamous Intraepithelial Lesion (HGSIL) [16]. Cervical cancer co-existing with a twin gestation has been reported in a nearby southwestern Nigerian hospital [13]. The antenatal period offers an opportunity for screening for cervical cancer, but uptake of many preventive health services in Nigeria is however very low, although these services are readily available and free in many instances. Only about 39% of pregnant women register at facilities that provide skilled care in pregnancy, a further lower proportion return for delivery and this number further dwindles at the postnatal clinic [17].

Infective cervical lesions such as cervicitis have been reported as causes of antepartum hemorrhage, but they are not significant enough to determine or affect obstetric outcome [18]. Chronic cervicitis presenting as heavy antepartum hemorrhage leading to preterm delivery is a rare occurrence. What predisposed this patient to chronic cervicitis is unknown, as she gave no history suggestive of symptoms of pelvic infection or STI treatment. The abuse of antibiotics and especially sub-optimal dosing may be a possible explanation, as these may result in the resolution of the active phase of infection but with a persistence of the chronic phase. The inappropriate use of antibiotics for treating other conditions may actually also predispose to this chronicity. The increasing size, vascularity of the uterus and the changes in the extracellular matrix composition of the cervix may be responsible for the bleeding occurring at this gestational age.¹⁶ This increase in size together with the cauliflower appearance of the cervix may have been picked earlier in pregnancy if a vaginal examination was done, but this patient had no indication for that. Routine vaginal examination in pregnancy has been challenged by some authors, based on research findings [19,20].

The continued bleeding and persistent uterine contractions necessitated delivery of the babies

in this case. Delivery was also very important as it could afford the opportunity to properly assess, stage and treat the suspected cervical cancer, which cannot be done with the fetuses still in-utero. Conservative management with delayed delivery would have been possible if an early diagnosis of chronic cervicitis was made certainly, but the unavailability of a quick frozen section analysis and the continued bleeding precluded this line of management. The need for caesarean section based on the persistent bleeding and contractions in the presence of the cervical pathology was discussed with the patient and her spouse. They were also counselled preoperatively that the suspicion of cervical malignancy would need to be confirmed by histology before definitive management. Hence postoperatively, the couple received the news of a benign cervical pathology with relief. Two factors may be responsible for the cessation of bleeding after delivery; the reversal of infective inflammation following antibiotics and delivery itself which results in reversal of pregnancy changes and a reduction in vascular supply to the cervix.

4. CONCLUSION

Infective lesions of the cervix are important benign causes of antepartum hemorrhage; the ability of chronic cervicitis to mimic exophytic cervical cancer is a consequence of physiologic changes in pregnancy which should be considered during patient evaluation. Cautious patient assessment should be done to ensure optimal care is given without undue risk to the fetus or mother.

CONSENT

All authors declare that written informed consent was obtained from the patient (or other approved parties) for publication of this case report and accompanying images. A copy of the written consent is available for review by the Editorial office/Chief Editor/Editorial Board members of this journal.

ETHICAL APPROVAL

It is not applicable.

ACKNOWLEDGEMENTS

The authors express sincere gratitude to the patient for permission to use the case for publication purpose.

COMPETING INTERESTS

Authors have declared that no competing interests exist.

REFERENCES

1. Takai IU, Sayyadi BM, Galadanci HS. Antepartum hemorrhage: A retrospective analysis from a northern nigerian teaching hospital. *Int J App Basic Med Res* 2017;7: 112-6.
2. Giordano R, Cacciatore A, Cignini P, Vigna R, Romano M. Antepartum Hemorrhage. *J. Prenat. Med.* 2010;4(1):12-16.
3. Trop I, Levine D. Hemorrhage during pregnancy: Sonography and MR imaging. *AJR Am J Roentgenol.* 2001;176:607-615.
4. Magann EF, Cummings JE, Niederhauser A, Rodriguez-Thompson D, McCormack R, Chauhan SP. Antepartum bleeding of unknown origin in the second half of pregnancy: a review. *Obstet Gynecol Surv.* 2005;60:741-745.
5. Sood AK, Sorosky JI. Invasive cervical cancer complicating pregnancy. *Obstet Gynecol Clin North Am.* 1998;25:343-52.
6. Anorlu RI, Orakwue CO, Oyeneyin L, Abudu OO. Late presentation of patients with cervical cancer to a tertiary hospital in Lagos: what is responsible? *Eur J Gynaecol Oncol.* 2004;25(6):729-32
7. Ijaiya MA, Aboyeji PA, Buhari MO. Cancer of the cervix in Ilorin, Nigeria West Afr J Med. 2004;23(4):319-22.
8. Rosalba Giordano, Alessandra Cacciatore, Pietro Cignini, Roberto Vigna, Mattea Romano, Antepartum haemorrhage *J Prenat Med.* 2010;4(1):12–16.
9. Ananth CV, Wilcox AJ. Placental abruption and perinatal mortality in the United States. *Am J Epidemiol.* 2001;153(4):332-7.
10. McDonald SD, Faught W, Gruslin A. Cervical Cancer During Pregnancy. *J Obstet Gynaecol Can.* 2002;24(6):491-8.
11. Apgar BS, Zoschnick LB. Triage of the abnormal Papanicolaou smear in pregnancy. *Prim Care.* 1998;25:483-503.
12. Jones WB, Shingleton HM, Russell A, Fremgen AM, Clive RE, Winchester DP, et al. Cervical carcinoma and pregnancy: A national patterns of care study of the American College of Surgeons. *Cancer.* 1996;77:1479-88.

13. Okunlola MA, Arowojolu AO, Adekunle OA, Owonikoko KM. Carcinoma of the cervix co-existing with multiple pregnancy: A case report. Afr J Med Med Sci. 2004; 33(2):177-8.
14. Amant F, Van Calsteren K, Vergote I, Ottevanger N. Gynecologic oncology in pregnancy. Crit Rev Oncol Hematol. 2008; 67:187–95.
15. Antonelli NM, Dotters DJ, Katz VI, Kuller JA. Cancer in pregnancy: a review of the literature. Obstet Gynecol Surv. 1996;5(1): 125-34.
16. Michael CW, Esfahani FM. Pregnancy-related changes: A retrospective review of 278 cervical smears. Diagn Cytopathol. 1997;17(2):99-107.
17. Ugboaja JO, Oguejiofor CB, Oranu EO, Igwegbe AO. Factors associated with the use of traditional birth attendants in Nigeria: A secondary analysis of 2013 Nigeria national demography and health survey. Niger J Gen Pract. 2018;16:45-52.
18. Oladipo A, Mathew J. Cervicitis decidualis: A rare cause of antepartum hemorrhage. J Low Genit Tract Dis. 2005;9(1):52-4.
19. Pattinson RE. Pelvimetry for fetal cephalic presentations at term. Cochrane Database of Systematic Reviews. 2001;(3):2001.
20. O'Donovan P, Gupta JK, Savage J, Thornton JG, Lilford RJ. Is routine antenatal booking vaginal examination necessary for reasons other than cervical cytology if ultrasound examination is planned? BJOG. 1988;95:556–9.

© 2019 Imaralu et al.; This is an Open Access article distributed under the terms of the Creative Commons Attribution License (<http://creativecommons.org/licenses/by/4.0>), which permits unrestricted use, distribution, and reproduction in any medium, provided the original work is properly cited.

Peer-review history:

The peer review history for this paper can be accessed here:

<http://www.sdiarticle3.com/review-history/50675>