



## Aesthetic neo-glans reconstruction after penis-sparing surgery for benign, premalignant or malignant penile lesions

Enzo Palminteri, Fernando Fusco, Elisa Berdondini & Andrea Salonia

To cite this article: Enzo Palminteri, Fernando Fusco, Elisa Berdondini & Andrea Salonia (2011) Aesthetic neo-glans reconstruction after penis-sparing surgery for benign, premalignant or malignant penile lesions, Arab Journal of Urology, 9:2, 115-120, DOI: [10.1016/j.aju.2011.06.013](https://doi.org/10.1016/j.aju.2011.06.013)

To link to this article: <https://doi.org/10.1016/j.aju.2011.06.013>



© 2011 Arab Association of Urology



Published online: 05 Apr 2019.



Submit your article to this journal [↗](#)



Article views: 725



View related articles [↗](#)



**Arab Journal of Urology**  
(Official Journal of the Arab Association of Urology)

www.sciencedirect.com



**ONCOLOGY/RECONSTRUCTION**

**ORIGINAL ARTICLE**

**Aesthetic neo-glans reconstruction after penis-sparing surgery for benign, premalignant or malignant penile lesions**

**Enzo Palminteri<sup>a,\*</sup>, Fernando Fusco<sup>b</sup>, Elisa Berdondini<sup>a</sup>, Andrea Salonia<sup>c</sup>**

<sup>a</sup> Center for Urethral and Genitalia Reconstructive Surgery, Arezzo, Italy

<sup>b</sup> Department of Urology, University Federico II, Naples, Italy

<sup>c</sup> Department of Urology, University Vita-Salute San Raffaele, Milan, Italy

Received 3 May 2011, Received in revised form 7 June 2011, Accepted 27 June 2011

Available online 15 September 2011

**KEYWORDS**

Penis;  
Carcinoma;  
Squamous cell;  
Lichen sclerosus;  
Glans reconstruction

**ABBREVIATIONS**

LS, lichen sclerosus; SCC, squamous cell carcinoma; STSG, split-thickness skin graft

**Abstract Purpose:** To describe the technique and results of penis-sparing surgery combined with a cosmetic neo-glans reconstruction for benign, pre-malignant or malignant penile lesions.

**Patients and methods:** Twenty-one patients (mean age 61 years) with penile lesions with a broad spectrum of histopathology underwent organ-sparing surgery with neo-glans reconstruction, using a free split-thickness skin graft harvested from the thigh. Three patients were treated by glans-skinning and glans-resurfacing, 10 by glanssectomy and neo-glans reconstruction, four by partial penectomy and a neo-glans reconstruction, and four by neo-glans reconstruction after a traditional partial penectomy.

**Results:** The mean follow-up was 45 months; all patients were free of primary local disease. All patients were satisfied with the appearance of the penis after surgery, and recovered their sexual ability, although sensitivity was reduced as a consequence of glans/penile amputation.

**Conclusion:** In benign, premalignant or malignant penile lesions, penis-sparing surgery combined with a cosmetic neo-glans reconstruction can be used to assure a normally appearing and functional penis, while fully eradicating the primary local disease.

© 2011 Arab Association of Urology. Production and hosting by Elsevier B.V. All rights reserved.

**Introduction**

Penile neoplasm is an uncommon malignancy, affecting fewer than one in 100,000 males in Europe and the USA; 78% of all tumours appear on the glans and/or prepuce [1,2]. Many of these

\* Corresponding author. Address: Center of Urethral and Genital Reconstruction, Via Fra' Guittone 2, 52100 Arezzo, Italy. Tel.: +39 3357012783; fax: +39 057527056.

E-mail address: enzo.palminteri@inwind.it (E. Palminteri).



lesions are red, moist patches which can be misdiagnosed as either a benign skin condition (i.e., Zoon's balanitis or lichen planus) or a premalignant lesion such as lichen sclerosus (LS) that, if left untreated, has the risk of progression to invasive squamous cell carcinoma (SCC) in 5–33% of cases [3]. Above all, both benign, premalignant and malignant lesions can cause pruritus, pain, bleeding, crusting and difficulties in retracting the foreskin, with subsequent overall psychosexual disability.

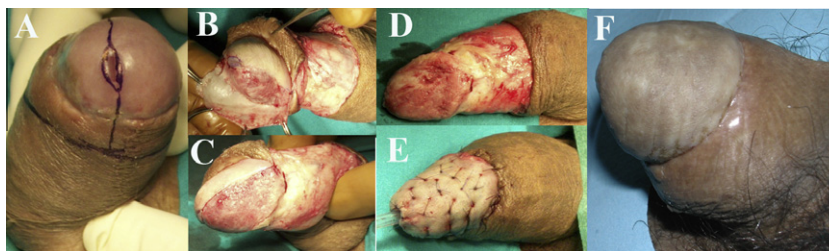
The treatment of benign, premalignant and malignant penile lesions has changed over time [4,5]. Traditional penile surgery is associated with a mutilating approach, eventually characterised by a high incidence of aesthetic, dysfunctional and psychological postoperative disorders [6–8]. In this context, the use of either medical or topical surgical treatments has been supported with the specific aim of maintaining a good functional and aesthetic penile shaft; topical chemotherapy, laser ablation, cryotherapy, and local excisions have been thus reported [3,4]. However, these techniques are associated with high failure rates and unsightly scarring that affects penile appearance and sexual activity.

Recently, in patients with either premalignant or malignant superficial lesions, alternative forms of surgical therapy, specifically aimed at preserving the phallus without jeopardising local cancer control, have been extensively suggested. These organ-sparing techniques, providing the reconstruction of an aesthetic neo-glans with no impairment of patient survival, have also been suggested for more advanced tumours [1–3,9].

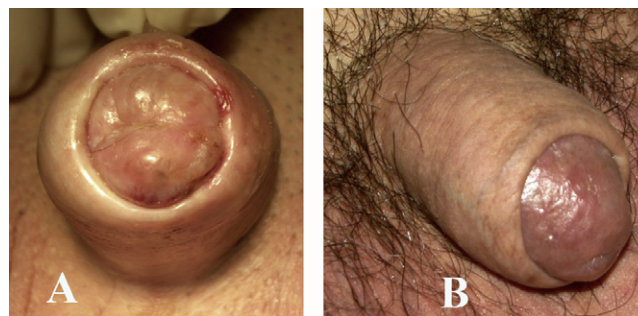
Here we report our surgical experience in 21 patients with either benign, premalignant or malignant penile lesions, using organ-sparing surgery developed to preserve a functional and aesthetic penile shaft at the same time, while fully eradicating the primary local disease.

### Patients and methods

From 2002 to 2010, 21 patients (mean age 61 years, range 41–78) with benign, premalignant or malignant penile lesions were treated at our centre. Of these men, 13 (62%) had already received previous medical or surgical treatments at different hospitals. All patients had preoperative biopsies taken to confirm the presence of the lesion. Likewise, patients with malignant lesions also had penile MRI to define the local extension of the tumour. Regional and metastatic disease was then clinically assessed with a physical examination and CT. Patients with suspected urethral stricture were evaluated by uroflowmetry, retrograde and voiding cysto-urethrography and urethroscopy. All patients underwent organ-preserving surgery with cosmetic reconstruction of a neo-glans using a free split-thickness skin graft (STSG) harvested from the thigh via four different surgical techniques.



**Figure 1** Glans skinning and glans resurfacing: SCC involving the glans and coronal sulcus (A). The glans epithelium is removed together with the distal foreskin (B–D). The skin graft is sutured and quilted over the stripped glans (E). Penile appearance 6 months after surgery (F).



**Figure 2** Glans skinning and glans resurfacing: LS and carcinoma in situ involving the glans penis: the significant tissue changes due to LS create a serious situation of functional disability and disfigurement of the penis (A). Penile appearance 6 months after surgery (B).

### Glans skinning and glans resurfacing

The penis is circumcised and the penile skin degloved. The glandular epithelium is fully removed up to the coronal sulcus. The STSG is harvested from the thigh using a manual dermatome, to be subsequently transplanted like an umbrella over the bed of the stripped glans. The graft is then tailored and quilted over the glans with multiple 6/0 polyglactin interrupted suture. The penile skin is sutured to the graft at the coronal sulcus (Figs. 1 and 2). This procedure is suitable for ‘crippling’ benign and premalignant lesions, and for malignant lesions which appear limited to the glandular epithelium.

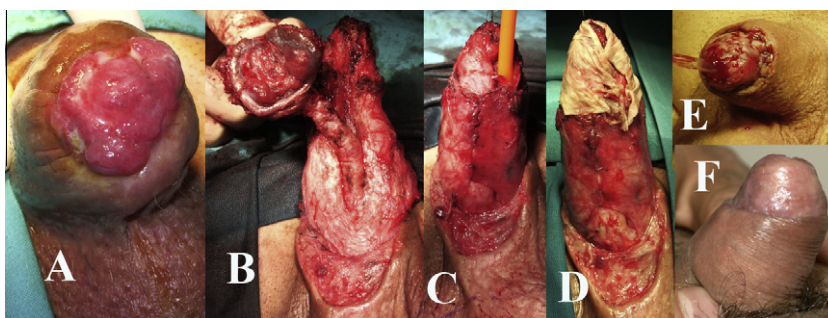
### Glansectomy and neo-glans reconstruction

The penis is circumcised and the penile skin is degloved. The glans is carefully segregated from the corpora cavernosa and the urethra is then distally sectioned. After removing the glans, the urethra is ventrally opened and the external urethral meatus is fixed to the tip of the corpora cavernosa. The STSG is therefore transplanted like an umbrella over the tips of the corpora cavernosa. The graft is tailored and quilted using interrupted stitches over the top of the corpora. Finally, the graft is fixed to the penile skin to recreate a neo-sulcus (Fig. 3). This procedure is usually suitable for malignant lesions which appear to infiltrate the glans.

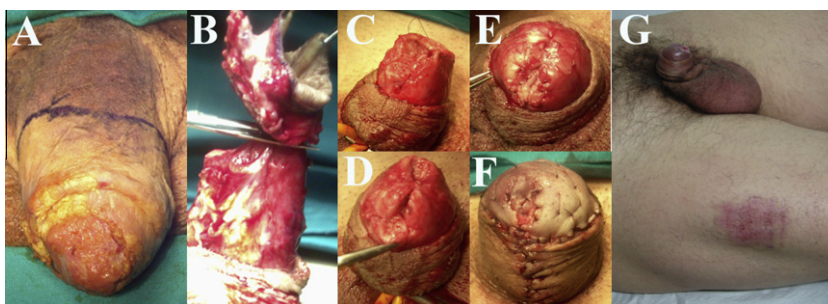
### Partial penectomy and neo-glans reconstruction

The partial penectomy is performed with resection margins of only few millimetres, according to the current techniques [10].





**Figure 3** Glansctomy and neo-glans reconstruction: SCC involving the glans penis (A). The glans is dissected from the corpora cavernosa and the urethra is distally sectioned (B). The urethral meatus is fixed to the summit of the corpora cavernosa (C). The STSG is transplanted like an umbrella over the summit of the corpora cavernosa (D). The graft is tailored and quilted using interrupted stitches over the top of the corpora. The graft is fixed to the penile skin to recreate a neo-sulcus (E). Penile appearance 6 months after surgery (F).



**Figure 4** Partial penectomy and neo-glans reconstruction: SCC involving the glans and penile shaft (A). Foreskin degloving and partial penectomy (B). The lateral edges of the residual corpora cavernosa are sutured together to create a hemispheric dome-shaped stump (C,D). The urethra is spatulated and the meatus is fixed on the new tip of the corpora cavernosa (E). The STSG is transplanted over the summit of the hemispheric stump (F). Penile appearance 6 months after surgery (G).

The lateral edges of the residual corpora cavernosa are sutured together to create a hemispheric dome-shaped stump. The urethra is then spatulated and the meatus is fixed on the new tip of the corpora cavernosa. The STSG is transplanted like an umbrella over the summit of the hemispheric stump, where it is quilted. The graft is eventually fixed to the penile skin with the aim to recreate a glandular neo-sulcus (Fig. 4). This procedure is suitable for malignant lesions which appear to involve the penile shaft.

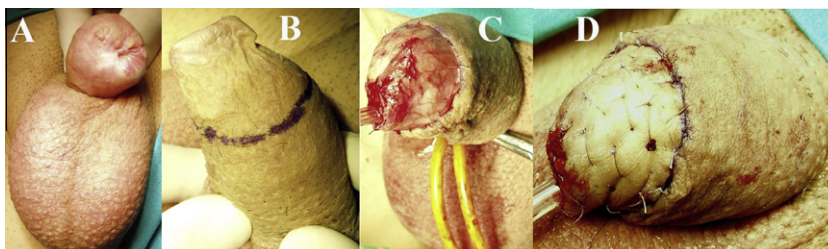
#### *Neo-glans reconstruction after previous traditional partial penectomy*

The top of the penile stump is skinned and the tip of the residual corpora cavernosa is reconverted to a hemispheric shape.

The urethra is spatulated and the meatus is fixed on the new tip of the corpora cavernosa. The STSG is transplanted like an umbrella over the summit of the hemispheric stump, where it is quilted. The graft is fixed to the penile skin thus recreating a glandular neo-sulcus (Fig. 5). This procedure is suitable for unaesthetic residual penile stumps after previous traditional partial penectomy.

In all cases a 12-F silicone Foley catheter is inserted, and a soft and humid dressing is applied covering the penis. The dressing is left in place for 3 days and the patient is requested to remain in bed. At 4 days after surgery the patient is mobilised and discharged from hospital if the graft is observed to be in good condition, with no penile haematoma, seroma or infection.

The mean (range) follow-up was 45 (4–104) months; the follow-up assessment included a careful examination of the



**Figure 5** Neo-glans reconstruction after previous traditional partial penectomy: The penile stump after partial penectomy (A). The top of the penile stump is skinned and the tip of the residual corpora is reconverted to a hemispheric shape (B,C). The STSG is transplanted like an umbrella over the summit of the hemispheric stump and fixed to the penile skin thus re-creating a neo-sulcus (D).

external genitalia, with groin inspection and palpation, and a biopsy of any suspicious area of penile induration or reddening, every 6 months. All patients with confirmed malignant tumours had a chest X-ray and full-body CT every 12 months.

## Results

Of 21 patients, three (14%) were treated by glans-skinning and glans-resurfacing, 10 (48%) by glansectomy and neo-glans reconstruction, four (19%) by partial penectomy with a neo-glans reconstruction, and four (19%) by neo-glans reconstruction after previous traditional partial penectomy. Table 1 details the surgical and pathological characteristics of all patients. In this context, 11 (52%) patients had urethral strictures and were

eventually treated with a meatotomy or a simple derivative urethrostomy. Four (19%) patients came to our referral surgical centre for neo-glans reconstruction after a traditional unaesthetic, partial penectomy for SCC. There were no significant immediate complications during or after surgery; five (24%) patients had partial graft loss and wound separation that was resolved after conservative management.

Patients were assessed for subjective satisfaction by self-report. All men were satisfied with the aesthetic results of the penile shaft after surgery; they also reported having recovered sexual functioning, although penile sensitivity was eventually reduced as a consequence of either the glandular skinning or glans/penile amputation. Patients who had neo-glans reconstruction after previous traditional partial penectomy reported

**Table 1** Patients' characteristics.

Patient (age, years)	Technique	Pathological staging	Associated urethral stricture	Associated urethroplasty
1 (65)	Glans skinning and glans resurfacing	CIS <sup>a</sup> , LS <sup>b</sup>	Meatal stricture	Meatotomy
2 (59)	Glans skinning and glans resurfacing	Zoon's balanitis	–	–
3 (69)	Glans skinning and glans resurfacing	SCC <sup>c</sup> (T1G1)	–	–
4 (41)	Glansectomy and neo-glans reconstruction	SCC (T1G2), LS	Penile stricture	Penile urethrostomy
5 (58)	Glansectomy and neo-glans reconstruction	SCC (T1G1), LS	–	–
6 (62)	Glansectomy and neo-glans reconstruction	SCC (T1G1)	Meatal stricture	Meatotomy
7 (64)	Glansectomy and neo-glans reconstruction	SCC (T1G2)	–	–
8 (60)	Glansectomy and neo-glans reconstruction	SCC (T1G2)	–	–
9 (60)	Glansectomy and neo-glans reconstruction	SCC (T1G2)	–	–
10 (62)	Glansectomy and neo-glans reconstruction	SCC (T1G1 in glans and T1G2 in Urethra), LS	Penile stricture	Perineal urethrostomy
11 (62)	Glansectomy and neo-glans reconstruction	SCC (T1G2)	Penile stricture	Penile urethrostomy
12 (46)	Glansectomy and neo-glans reconstruction	Severe Dysplasia, LS	–	–
13 (64)	Glansectomy and neo-glans reconstruction	Severe Dysplasia	Bulbar stricture	Perineal urethrostomy
14 (78)	Partial penectomy and neo-glans reconstruction	SCC (T1G1), LS	–	–
15 (50)	Partial penectomy and neo-glans reconstruction	SCC (T1G1), Ca in situ	–	–
16 (72)	Partial penectomy and neo-glans reconstruction	SCC (T2G1)	Meatal stricture	Meatotomy
17 (74)	Partial penectomy and neo-glans reconstruction	SCC (T2G2)	Penile and bulbar stricture	Perineal urethrostomy
18 (58)	Neo-glans reconstruction following previous traditional partial penectomy	LS	Penile and bulbar stricture	Perineal urethrostomy
19 (67)	Neo-glans reconstruction following previous traditional partial penectomy	LS	Bulbar stricture	Perineal urethrostomy
20 (46)	Neo-glans reconstruction following previous traditional partial penectomy	LS	–	–
21 (57)	Neo-glans reconstruction following previous traditional partial penectomy	Severa dysplasia, LS	Penile and bulbar stricture	Perineal urethrostomy

<sup>a</sup> Carcinoma in situ.

<sup>b</sup> Lichen sclerosus.

<sup>c</sup> Squamous cell carcinoma.

an improvement in the appearance of the penis, and recovery of their sexual ability. Finally, there were no immediate or later complications at the harvesting site.

All patients with SCC showed no evidence of local recurrence of the primary tumour. Two of the 13 patients with SCC showed a reddened lesion after primary excision, requiring a biopsy, although the final histology showed no tumour recurrence. All patients with SCC had a clinical N0, M0 stage and were not submitted to a inguinal lymph node dissection at the time of penile surgery. By contrast, three patients had bilateral inguinal node enlargement at the 12-month CT and had a bilateral groin dissection (patients 4, 7 and 16; Table 1). Final pathology of the lymph nodes showed metastatic disease and the patients were then treated with a multimodal approach combining radio- and chemotherapy. Of these, one patient (patient 16) died from disease progression, while the other two remained alive at the most recent follow-up assessment.

## Discussion

Laser ablation or other conservative therapies for penile lesions aim to remove the diseased tissue, but the disease can eventually recur in unrecognized premalignant foci arising within the unstable epithelium after a partial procedure. Moreover, pre-cancerous lesions often show recalcitrance after conservative treatments, with final development of SCC in 5–33% of cases [4,9,11–13]. Recently, plastic and reconstructive surgical techniques have been developed to reduce the functional and psychological morbidity in patients who have undergone mutilating penile surgery [1–3,9,14–17]. In selected patients, the use of these relatively new plastic approaches with total glans reconstruction provided a satisfactory aesthetic and functional outcome, without sacrificing rigorous cancer control [1–3].

In this context, when using total glans skinning and resurfacing, the epithelium is completely removed, thus reducing the potential risk of either disease recurrence or progression in different sites, as compared with the primary lesion [3]. On the other hand, the partial repair of the glans could easily create a disfiguring and dysfunctional scar. Moreover, for LS which involves the male genitalia, a progressive crippling disease scar has been frequently described, with subsequent phimosis that might promote poor local hygiene and chronic inflammatory conditions, potentially being the aetiological factors promoting penile malignancy (Fig. 2). In this case, LS is frequently associated with dysplasia, thus some authors have suggested that LS should be considered as a formal pre-cancerous lesion [11–13,18]. In particular, in the present series, in 23% of patients the tumour was associated with LS, confirming a close correlation between these penile pathologies. Thus, in cases of LS, total excision of the dysplastic glandular epithelium reduces the risk of cancer developing; likewise, this approach might solve the problem of discomfort during sexual intercourse, which is frequently a consequence of the scarred glans.

For glans resurfacing we prefer to not use buccal mucosa, because in our experience, when a buccal mucosa graft was used in staged penile urethroplasty, there was desquamation of the graft in some patients due to contact of the oral mucosa with air, as buccal mucosa is adapted to a humid environment, not a dry one. In patients with LS, the use of a skin graft could

lead to disease recurrence, even if it seems that excision of much of the diseased tissue by ample circumcision reduces this risk.

Reconstructive surgery can also be used in benign but invalidating lesions. For example, in the present series, one patient with persistent extensive Zoon's balanitis was able to resume sexual activity after glans skinning and glans resurfacing.

In patients who had a glansectomy or partial penectomy, length and sensitivity decreased as an inevitable and foreseeable consequence of glans/penile amputation, but the cosmetic appearance of the neo-glans was similar to that of a native glans. The patients were then able to fully regain sexual functioning, with a favourable psychological impact. In these patients, the aesthetic appearance of the penis was subjectively better than that in patients who had other traditional techniques, thus promoting the positive psychological effect. This last aspect is of paramount importance, as many patients with penile cancer are significantly reluctant to undergo partial or total penectomy, because of the perception of compromised masculinity [3].

It was previously reported that ≈80% of penile malignancies are probably amenable to these penis-preserving techniques, as most of the lesions occur distally and involve only the superficial epithelium of the glans [2]. In this context, it is important to highlight that in patients with superficial penile cancer associated with pre-cancerous lesions due to LS, any conservative treatment does not actually remove these lesions, thus potentially allowing cancer recurrence over time, which might arise from an unstable epithelium bordering the primary lesion. Therefore, rigorous patient selection is compulsory to technically provide an aesthetic solution with effective long-term cancer control.

As suggested by the European Association of Urology Guidelines [19], in malignant lesions we used MRI to define the extent of the penile lesion. This method has been useful to define whether the lesion was limited to the glans or involved the corpora, and therefore directing treatment to glansectomy or partial penectomy.

We highlight that 52% of patients with penile lesions had a urethral stricture requiring surgical treatment; in 11 of these urethral strictures, most (six) were due to LS which involved the glans but also the urethra (Table 1). This confirms the need for a careful urethral evaluation before planning any genital surgery in these patients.

As to the assessment of patient satisfaction, similarly to other leading authors [20], patients were simply interviewed during the follow-up. The main limitation of this and other series is the lack of formal data on functional outcome after these techniques. Patients were assessed clinically for cosmesis, and were questioned about satisfaction and sexual function, but outcomes were not collated using any validated questionnaires. This remains a goal for the future and might be more effectively achieved using surgery-specific Patient Reported Outcome Measures questionnaires.

In conclusion, penis-sparing surgery coupled with neo-glans reconstruction is an adequate treatment in rigorously selected patients with either benign, premalignant or malignant penile lesions. While preserving a good aesthetic appearance of the penile shaft, the goal of all these techniques is to maintain a functional penis in terms of both urination and sexual function, without jeopardising cancer control.

### Conflict of interest

I declare that me and my co-Authors don't have any conflict of interest.

### Acknowledgement

The surgical techniques described in this article were developed and suggested to us by Dr. Aivar Bracka, without whose teaching and guidance it would not have been possible to obtain these positive results.

### References

- [1] Brown CT, Minhas S, Ralph DJ. Conservative surgery for penile cancer: subtotal glans excision without grafting. *BJU Int* 2005;**96**:911–2.
- [2] Pietrzak P, Corbishley CM, Watkin N. Organ-sparing surgery for invasive penile cancer: early follow-up data. *BJU Int* 2004;**94**:1253–7.
- [3] Hadway P, Corbishley CM, Watkin NA. Total glans resurfacing for premalignant lesions of the penis: initial outcome data. *BJU Int* 2006;**98**:532–6.
- [4] Hegarty PK, Rees RW, Borley NC, Ralph DJ, Minhas S. Contemporary management of penile cancer. *BJU Int* 2008;**102**:928–32.
- [5] Bracka A. Glans resection and plastic repair. *BJU Int* 2009;**105**:136–44.
- [6] Opjordsmoen S, Fossa SD. Quality of life in patients treated for penile cancer. A follow-up study. *Br J Urol* 1994;**74**:652–7.
- [7] D'Ancona CA, Botega NJ, De Moraes C, Lavoura ND, Santos NR, Netto NR. Quality of life after partial penectomy for penile carcinoma. *Urology* 1997;**50**:593–6.
- [8] Romero FR, Pereira Dos Santos Romero KR, Elias De Mattos CR, Camargo Garcia CR, De Carvalho Fernandes R, Cardenuto Perez MD. Sexual function after partial penectomy for penile cancer. *Urology* 2005;**66**:1292–5.
- [9] Palminteri E, Berdondini E, Lazzeri M, Mirri F, Barbagli G. Resurfacing and reconstruction of the glans penis. *Eur Urol* 2007;**52**:893–900.
- [10] Minhas S, Kayes O, Hegarty P, Kumar P, Freeman A, Ralph D. What surgical resection margins are required to achieve oncological control in men with primary penile cancer? *BJU Int* 2005;**96**:1040–3.
- [11] Cubilla AL, Velazquez EF, Young RH. Epithelial lesions associated with invasive penile squamous cell carcinoma: a pathologic study of 288 cases. *Int J Surg Pathol* 2004;**12**:351–64.
- [12] Nasca MR, Innocenzi D, Micali G. Penile cancer among patients with genital lichen sclerosus. *J Am Acad Dermatol* 1999;**41**:911–4.
- [13] Powell J, Robson A, Cranston A, Wojnarowska F, Turner R. High incidence of lichen sclerosus in patients with squamous cell carcinoma. *Br J Dermatol* 2001;**145**:85–9.
- [14] Fonseca AG, Rabelo GN, Vidal KS, de Sousa FJ. Glandectomy with preservation of corpora cavernosa in the treatment of penile carcinoma. *Int Brazilian J Urol* 2003;**29**:437–40.
- [15] Bissada N. Organ-sparing surgery for invasive penile carcinoma. *BJU Int* 2005;**95**:1118–9.
- [16] Greenberger ML, Lowe BA. Penile stump advancement as an alternative to perineal urethrostomy after penile amputation. *J Urol* 1999;**161**:893–4.
- [17] Parkash S, Ananthakrishnan N, Roy P. Refashioning of phallus stumps and phalloplasty in the treatment of carcinoma of the penis. *Br J Surg* 1986;**73**:902–5.
- [18] Barbagli G, Palminteri E, Mirri F, Guazzoni G, Turini D, Lazzeri M. Penile carcinoma in patients with genital lichen sclerosus: a multicentric survey. *J Urol* 2006;**175**:1359–63.
- [19] Algaba FS, Horenblas G, Pizzocaro L, Piva E, Solsona T, Windahl EAU. Guidelines on penile cancer. *Eur Urol* 2002;**42**:199–203.
- [20] Shabbir MA, Muneer J, Kalsi CJ, Shukla E, Zacharakis G, Garaffa D, et al. Glans resurfacing for the treatment of carcinoma in situ of the penis. Surgical technique and outcomes. *Eur Urol* 2011;**59**:142–7.