



# Clinical and Echocardiography Characteristics of in-situ Pulmonary Artery Thrombosis in Morocco: Case Series about 4 Patients

**Haless Kamal <sup>a\*</sup>, Jama Dounia <sup>a</sup>, Boucetta Abdoullah <sup>a</sup>,  
R. Habbal <sup>a</sup>, A. Drighil <sup>a</sup>, L. Azouzi <sup>a</sup>, G. Benouna <sup>a</sup>,  
S. Arous <sup>a</sup> and M. Haboub <sup>a</sup>**

<sup>a</sup> *Service of Cardiology, Ibn Rochd University Hospital, Morocco.*

## **Authors' contributions**

*This work was carried out in collaboration among all authors. Authors HK and JD conceived the presented idea. Author HK developed the theory and performed the computations. Author BA verified the analytical methods. Author JD encouraged author BA to investigate. Authors RH, AD, LA and GB supervised the findings of this work. All authors discussed the results and contributed to the final manuscript. All authors read and approved the final manuscript.*

## **Article Information**

### **Open Peer Review History:**

This journal follows the Advanced Open Peer Review policy. Identity of the Reviewers, Editor(s) and additional Reviewers, peer review comments, different versions of the manuscript, comments of the editors, etc are available here: <https://www.sdiarticle5.com/review-history/102009>

**Case Study**

**Received: 15/04/2023**

**Accepted: 19/06/2023**

**Published: 07/08/2023**

## **ABSTRACT**

**Background:** Thromboembolic disease is the third leading cause of cardiovascular death. In recent years, several lines of evidence have indicated the possibility of de novo thrombus generation in pulmonary arteries without deep vein thrombus (DVT) in the lower extremities. Pulmonary artery thrombosis is a very rare diagnostic entity, usually manifested by embolic migration from another venous site, and may form by in situ thrombus. The aim of this study is to evaluate the clinical and echocardiography (TTE) data of pulmonary artery thrombosis in situ

\*Corresponding author: E-mail: [dr.kamalhaless@gmail.com](mailto:dr.kamalhaless@gmail.com), [med.kamalhaless@gmail.com](mailto:med.kamalhaless@gmail.com);

(PATIS). This is a mini-series about 4 cases seen in the intensive cardiac care unit (ICCU) at the cardiology department of University Hospital of Ibn Rochd -Casablanca between 01/01/2023 to 01/04/2023.

**Case Presentation:** We present a mini series of 4 patients; 3 women and a man, admitted to the ICCU for high-risk pulmonary artery thrombosis. The mean age of 64 years old. Two patients of the feminine sex had neoplasia, a man sedentary because of a bilateral lymphedema in the lower limbs. The last patient was a woman under oestro-progestatif pills, au total, all of these factors represent probably the main factors of their thromboembolic events. Clinically, all of them had a dyspnea and angina. A bed echocardiography objectifying evidence of acute cor pulmonale associate of right ventricle dysfunction and pulmonary artery thrombosis in situ (PATIS). we introduce Immediately non-fractional heparin (NFH) after the diagnostic of the PATIS without waiting the results of the thoracic angio-CT, no one initially had thrombolysis. The prognostic was somber, 3 out of 4 patients died from cardiogenic shock during hospitalization. In our opinion, the main effect was for co-morbidities such as age, neoplasia profile and uncontrolled diabetes.

**Conclusions:** There is much theory regarding the pathophysiology of pulmonary artery thrombus in situ, but the main pathogenicity is considered to be local pulmonary factors, including pulmonary vascular endothelial cell dysfunction, hypoxia and inflammation.

**Keywords:** Pulmonary Artery Thrombus in Situ (PATIS); echocardiography.

## ABBREVIATIONS

DVT : Deep Vein Thrombus  
TTE : Echocardiography  
PATIS : Pulmonary Artery Thrombosis in Situ  
ICCU : The Intensive Cardiac Care Unit  
NFH : Non-Fractional Heparin  
CTPA : Computed Tomography Pulmonary Angiography  
DOACs : Direct Oral Anticoagulants  
PA : Pulmonary Artery  
Ao : Aorta  
RPA : Right Pulmonary Artery  
LPA : Left Pulmonary Artery

## 1. INTRODUCTION

Thromboembolic disease is the third leading cause of cardiovascular death. In recent years, several lines of evidence have indicated the possibility of de novo thrombus generation in pulmonary arteries without deep vein thrombus (DVT) in the lower extremities [1]. The aim of this study is to evaluate the clinical and echocardiography (TTE) data of pulmonary artery thrombosis in situ (PATIS), about 4 cases seen in the intensive cardiac care unit (ICCU) at the cardiology department of University Hospital of Casablanca between 01/01/2023 to 01/04/2023.

## 2. CASE PRESENTATION

We present a mini series of 4 patients; 3 women and a man, admitted to the ICCU for high-risk pulmonary artery thrombosis. The profile of our

patients presented initially by a mean age of 64 years old only one had a 45-year-old. Looking of the cardiovascular risk factors two patients are hypertensive, three are diabetic type-II under insulin therapy one of these was totally uncontrolled at the moment of the admission and she had a diabetic acidosis's and represented cause of the high risk of mortality. all the women where menopausal. Two patients of the feminine sex had neoplasia; the first one had a breast cancer treated surgically by mastectomy; then she received five radiotherapy sessions, in the other hand, one had gallbladder cancer under surveillance protocol, a man sedentary because of a bilateral lymphedema in the lower limbs. The last patient was a woman under oestro-progestatif pills, au total, all of these factors represent probably the main factors of their thromboembolic events.

Clinically, all of them had a dyspnea and angina, one of the had hemoptysis . All of them had a normal blood pressure but with tachycardia with moyen heart rate of 119 bpm. on electrocardiography, all had a sinus rhythm two of them has the aspect of s1q3 with a negative T waves from the V1 to the V4. All the patients had urgently a bed echocardiography which it objectifying evidence of acute cor pulmonale associate of right ventricle dysfunction and PATIS (Figs.1 to 6).

Biologically, all of them had a positive level of troponin and BNP; PESI was positive for all the patient with Mayen of 4 points. three patients complicated pulmonary infraction confirmed by

CT scan and treated by the association of amoxicillin and clavulanic acid. No one had inferior member thrombosis. Therapeutically, we introduce Immediately non-fractional heparin (NFH) after the diagnostic of the PATIS without waiting the results of the thoracic angio-CT, no one initially had thrombolysis. the average period of hospitalization was 10 days only one has been discharge of dawn intensive level unity. The prognostic was somber, 3 out of 4 patients (two women and one man) died from cardiogenic shock during hospitalization. In our opinion, the main effect was for co-morbidities such as age, neoplasia profile and uncontrolled diabetes.

### 3. DISCUSSION

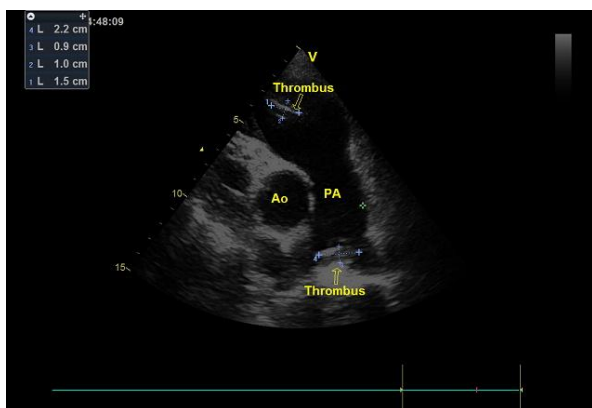
Pulmonary artery thrombosis is a complex condition with diverse clinical presentations, making its diagnosis and management challenging [1]. This mini-series underscores the significance of integrating clinical assessment with echocardiography, specifically transthoracic echocardiography (TTE), to establish an accurate diagnosis and guide therapeutic interventions.

Clinical evaluation plays a crucial role in the initial assessment of patients suspected of having pulmonary artery thrombosis. The patient's medical history, including risk factors such as obesity, immobilization, recent surgery, provides valuable insights [2]. The presenting symptoms of dyspnea, pleuritic chest pain, and hemoptysis are typical but nonspecific, as they

can be observed in other cardiopulmonary conditions. Therefore, a high index of suspicion is necessary to consider pulmonary artery thrombosis in the differential diagnosis. The physical examination findings of tachypnea, increased jugular venous pressure, and a loud pulmonic component of the second heart sound further supported the suspicion of a pulmonary embolic event (1-2).

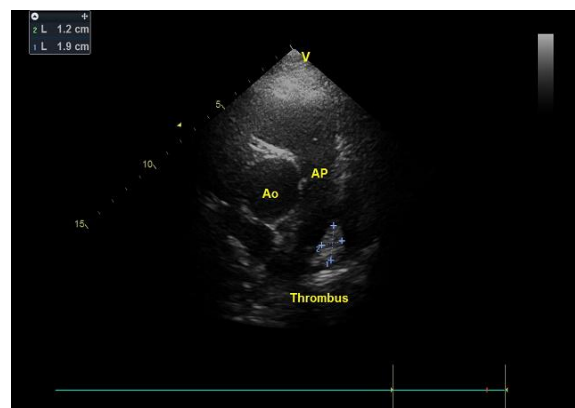
To aid in the diagnostic process, laboratory investigations could be performed. D-dimer levels, which reflect the breakdown of fibrin clots, can be elevated in various conditions, including pulmonary artery thrombosis [3]. However, elevated D-dimer levels lack specificity and can be influenced by other factors such as age, inflammation, and malignancy. Arterial blood gas analysis and coagulation profiles provide additional information to assess the patient's respiratory status and coagulation parameters [4].

Echocardiography, particularly TTE, is a valuable imaging modality in the evaluation of pulmonary artery thrombosis. It provides real-time information on cardiac structure and function, as well as direct visualization of thrombi within the pulmonary vasculature [5]. It can also reveal right ventricular dilation, paradoxical septal wall motion, and the presence of thrombi within the main pulmonary artery and its branches [5]. These findings are normally consistent with acute right ventricular strain due to pulmonary artery thrombosis [5,6].



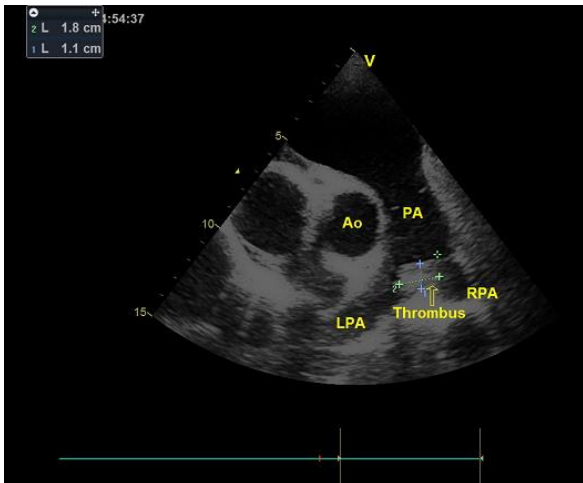
**Fig. 1. First patient, PSAX view on echocardiography showing the presence of a thrombus within the right ventricle measuring 15x10mm, another thrombus located at the bifurcation of the pulmonary artery measuring 22x9mm**

Legends PA : Pulmonary Artery , Ao : Aorta



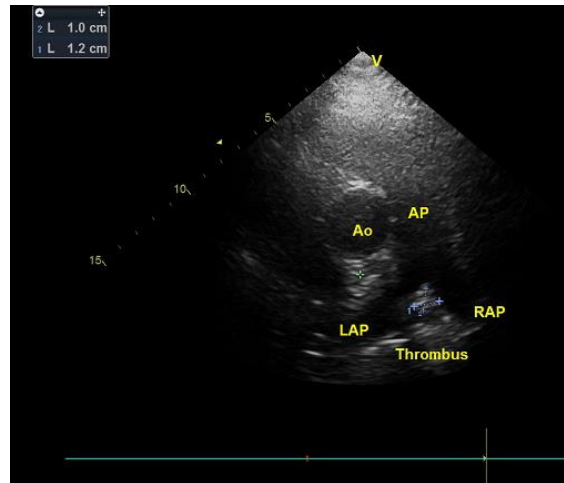
**Fig. 2. Second patient, PSAX view on echocardiography showing the presence of a thrombus located at the bifurcation of the pulmonary artery measuring 19x12 mm**

Legends PA : Pulmonary Artery , Ao : Aorta



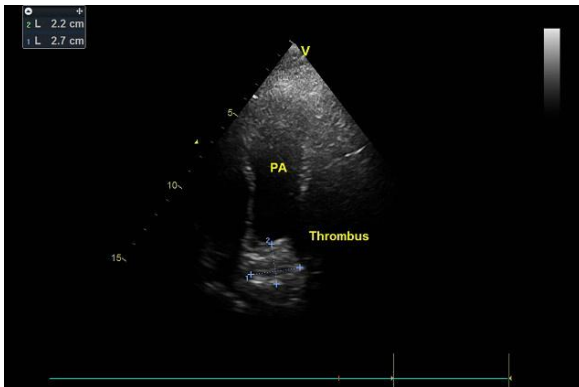
**Fig.3. Second patient, after a few days of anticoagulation, we performed an echocardiography control showing the simple regression of 1 mm. The pulmonary artery thrombus measuring 18x11mm.**

*Legends PA: Pulmonary Artery, Ao: aorta, RPA: right Pulmonary Artery, LPA: Left Pulmonary Artery,*



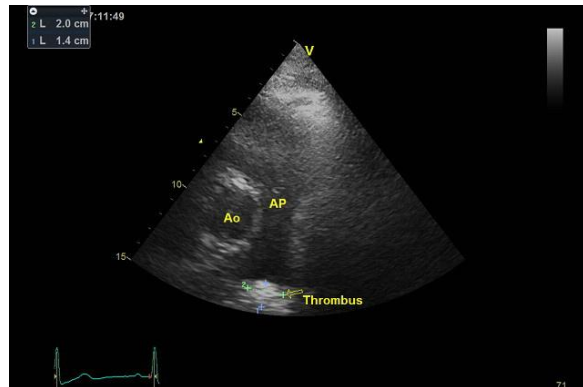
**Fig.4. Second patient, 2 weeks of anticoagulation, we note a significant regression of the pulmonary artery thrombus measuring 10x12mm, with diapers of the occlusive aspect.**

*Legends PA: Pulmonary Artery, Ao: aorta, RPA: right Pulmonary Artery, LPA: Left Pulmonary Artery,*



**Fig.5. The Fourth patient, PSAX echocardiographic view in releasing the pulmonary artery we notice the presence of a thrombus located at the bifurcation of the pulmonary artery with occlusive aspect measuring 22x27mm**

*Legends PA: Pulmonary Artery*



**Fig.6. The Fourth patient, PSAX echocardiographic view in releasing the pulmonary artery we note the presence of a thrombus located at the bifurcation of the pulmonary artery with occlusive aspect measuring 22x9mm**

*Legends PA: Pulmonary Artery, Ao : Aorta*

However, it is important to note that the diagnosis of pulmonary artery thrombosis can pose challenges, especially in cases of distal or small-vessel involvement. Thrombi within the pulmonary artery are not always easily visualized using TTE alone [6]. In such instances, additional imaging modalities such as computed tomography pulmonary angiography (CTPA) or ventilation-perfusion scanning may be necessary to complement the TTE findings and achieve a definitive diagnosis [7,8].

The management of pulmonary artery thrombosis centers around prompt therapeutic interventions to prevent further thrombus propagation, minimize right ventricular strain, and reduce the risk of complications. Anticoagulation therapy with heparin is typically initiated immediately, followed by transition to oral anticoagulants such as warfarin or direct oral anticoagulants (DOACs) [9]. Close monitoring of the patient's clinical status, laboratory values, and imaging studies, including follow-up TTE, are

essential to assess treatment response and guide further management decisions.

#### 4. CONCLUSIONS

Pulmonary artery thrombosis is a very rare diagnostic entity, usually manifested by embolic migration from another venous site, and may form by in situ thrombus. There is much theory regarding the pathophysiology of pulmonary artery thrombus in situ, but the main pathogenicity is considered to be local pulmonary factors, including pulmonary vascular endothelial cell dysfunction, hypoxia and inflammation. Radiation therapy is a major iatrogenic factor in the pathogenicity of pulmonary artery thrombus.

#### CONSENT

As per international standard or university standard, patient(s) written consent has been collected and preserved by the author(s).

#### ETHICAL APPROVAL

As per international standard or university standard written ethical approval has been collected and preserved by the author(s).

#### COMPETING INTERESTS

Authors have declared that no competing interests exist.

#### REFERENCES

1. Konstantinides SV, Meyer G, Becattini C, et al. 2019 ESC Guidelines for the diagnosis and management of acute pulmonary embolism developed in collaboration with the European Respiratory Society (ERS). *Eur Heart J*. 2020;41(4):543-603. DOI: 10.1183/13993003.01647-2019
2. Lang IM, Pesavento R, Bonderman D, Yuan JX. Risk factors and basic

mechanisms of chronic thromboembolic pulmonary hypertension: A current understanding. *Eur Respir J*. 2013;41(2):462-468.

DOI: 10.1183/09031936.00049312

3. Miniati M, Monti S, Bottai M, et al. Survival and restoration of pulmonary perfusion in a long-term follow-up of patients after acute pulmonary embolism. *Medicine (Baltimore)*. 2006;85(5):253-262. DOI:10.1097/01.md.0000236952.87590.c8
4. Dalen JE. Pulmonary embolism: What have we learned since Virchow? *Natural history, pathophysiology, and diagnosis*. *Chest*. 2002;122(4):1440-1456. DOI: 10.1378/chest.122.4.1440
5. Ribeiro A, Lindmarker P, Johnsson H, et al. Pulmonary embolism: One-year follow-up with echocardiography Doppler and five-year survival analysis. *Circulation*. 1999;99(10):1325-1330. DOI: 10.1161/01.cir.99.10.1325
6. Jaff MR, McMurtry MS, Archer SL, et al. Management of massive and submassive pulmonary embolism, iliofemoral deep vein thrombosis, and chronic thromboembolic pulmonary hypertension: A scientific statement from the American Heart Association. *Circulation*. 2011;123(16):1788-1830.
7. Ghaye B, Ghuyssen A, Bruyère PJ, D'Orio V. Dilemmas in the diagnosis of acute pulmonary embolism on CT pulmonary angiography. *Quant Imaging Med Surg*. 2016;6(1):51-60. DOI: 10.1148/rg.261055062
8. Ghaye B, et al. Pulmonary embolism. Quantitative imaging in medicine and surgery. 2016;6(4):406-424. DOI: 10.1177/0284185116651003
9. Rose PS, Punjabi NM, Pearse DB. Treatment of right heart thromboemboli. *Chest*. 2002;121(3):806-814. DOI: 10.1378/chest.121.3.806

© 2023 Kamal et al.; This is an Open Access article distributed under the terms of the Creative Commons Attribution License (<http://creativecommons.org/licenses/by/4.0>), which permits unrestricted use, distribution, and reproduction in any medium, provided the original work is properly cited.

*Peer-review history:*

*The peer review history for this paper can be accessed here:*  
<https://www.sdiarticle5.com/review-history/102009>