



# **Immediate Tooth Autotransplantation into Fresh Extraction Sockets: A Case Series and Literature Review**

**Andreas Sakkas<sup>a\*</sup>, Robert A. Mischkowski<sup>a#</sup> and Oliver C. Thiele<sup>a</sup>**

<sup>a</sup> Department of Oral, Maxillofacial and Facial Plastic Surgery, Ludwigshafen Hospital, Ludwigshafen, Germany.

## **Authors' contributions**

*This work was carried out in collaboration among all authors. All authors read and approved the final manuscript.*

## **Article Information**

DOI: 10.9734/JAMMR/2021/v33i2431226

## **Open Peer Review History:**

This journal follows the Advanced Open Peer Review policy. Identity of the Reviewers, Editor(s) and additional Reviewers, peer review comments, different versions of the manuscript, comments of the editors, etc are available here: <https://www.sdiarticle5.com/review-history/81104>

**Case Study**

**Received 20 October 2021**  
**Accepted 22 December 2021**  
**Published 24 December 2021**

## **ABSTRACT**

Autologous tooth transplantation has been used in various indications to replace missing teeth. In this case series, we investigated the long-term outcomes following immediate tooth autotransplantation into fresh extraction sockets in young individuals in our center. A consecutive retrospective study was conducted on patients treated at the clinic of Oral and Plastic Maxillofacial Surgery at Ludwigshafen hospital in Germany. Demographic factors, indication for tooth autotransplantation, donor site, and recipient site were extracted from patient records. The clinical and radiographic outcomes of 11 autotransplanted teeth were evaluated in a follow-up observation period ranging from 20 to 78 months. A total of 11 tooth transplantations were carried out in nine patients during the study period. Chronic apical periodontitis, non-restorable extended caries, hypodontia, ectopical eruption and accidental trauma were the reasons for tooth transplantation. Overall, nine third molars, one second molar, and one canine were autotransplanted. Donor teeth were mandibular third molars in seven cases, maxillary third molars in two cases, a maxillary second molar in one case, and a maxillary canine in one case. Six donor teeth had completely formed roots and five had incompletely developed roots and an open apex at the time of surgery. After a mean follow-up of 44 months, 10 cases (90.9%) were successful; one case failed because of root resorption and uneventful bone remodeling. In four cases, external root resorption was

<sup>#</sup>Professor and Head;

\*Corresponding author: E-mail: [ansakkas@yahoo.com](mailto:ansakkas@yahoo.com);

observed. No pulp revascularization was observed during the recall period. The survival rate and success rate of tooth autotransplantation were 90.9% and 63.6%, respectively. Our results are in agreement with other published observations. We conclude that autologous tooth transplantation into fresh extraction sockets in young individuals has a high long-term success rate. Although the indications for autotransplantation are quite narrow, careful patient selection coupled with an appropriate surgical technique can lead to exceptional long-term functional results.

**Keywords:** *Tooth autotransplantation; complete tooth root formation; mature third molars; extraction sockets.*

## 1. INTRODUCTION

Fong reported the first successful autotransplantation of third molars in 1953. However, the technique of autologous tooth transplantation was not well described until three years later, by Hale [1,2], and the major principles of his technique are still followed today. Since then, many clinicians have reported their experience, validating autologous tooth transplantation in modern dentistry. In the 1960s, Slagsvold and Bjercke established a protocol for autotransplanting teeth. Indications for transplantation, surgical technique, and follow-up guidelines were included. The predictability of their method was supported by a long-term follow-up study, which showed a 90% survival rate of the transplanted teeth [3,4].

However, lack of understanding of biological principles and poor clinical results in early years led practitioners to underestimate the application of this tooth replacement technique in daily practice. Another barrier to acceptance of this method has been the misconception that autotransplantation can only be successful when immature, developing teeth are transplanted. It is postulated that immature teeth are better for transplantation because of alveolar bone proprioception, pulp revascularization, and continued root development [5-9].

Since then, tooth autotransplantation has progressed, as evidenced by the high success rates reported over the past two decades [5-9,10,11, 12]. Interest in this technique has been revived because it provides functional adaptation and aesthetics, alveolar bone induction, preservation of the alveolar bone ridge, and reestablishment of a normal alveolar process [13]. Consequently, tooth autotransplantation is now established as a viable option for tooth replacement in appropriately selected patients [13-20, 10-12]. These include growing patients with missing teeth due to trauma or agenesis/aplasia, non-restorable teeth, teeth with

a poor long-term survival prognosis in long-term, and orthodontic problems such as reposition of ectopical erupted canines [21,22,13-20]. However, autologous tooth transplantation is rarely indicated; dental implants are often used instead, even though they are contraindicated in growing patients. Autotransplantation would be a viable alternative in these young patients. Transplantation is also much cheaper than implant treatment [23,10].

One of the basic prerequisites for successful autotransplantation is an appropriate recipient site. Suitability of the recipient site varies according to the timing of tooth loss [24,10-12]. For patients requiring the replacement of teeth that cannot be retained, autotransplantation can be performed immediately after extraction. In such cases, the recipient site generally has adequate bone and can easily be prepared to allow for good approximation between the transplanted tooth and bone [25,26]. For patients with conditions such as congenitally missing teeth or early tooth loss, the recipient site for autotransplantation needs to be created surgically, which often provides inadequate bone support for the transplanted tooth [26]. Inadequate buccolingual width at the recipient site may cause protrusion of the roots through bone dehiscence and alveolar ridge resorption [27]. Aoyama et al. (2012) reported narrow recipient sites in all failed mature tooth autotransplantations [28]. Graft materials could be placed over the exposed root to promote bone regeneration. However, the ability of this method to facilitate tooth autotransplantation in patients with bone resorption at the recipient site has not been well investigated [29].

The autotransplantation of third molars has become a useful and acceptable treatment option for missing posterior teeth in the human dentition [25,26,28,24,30-33]. The transplantation of immature third molars is a cost-effective treatment alternative to implants and can be performed in young patients [23,33-35].

Transplanted immature third molars can then be moved orthodontically and retain their potential to induce alveolar bone growth during eruption. Furthermore, the formation of a functional periodontal ligament allows teeth to erupt, promoting bony infill at deficient sites. In addition, the natural gingival contour is often superior to that achieved with prosthetic alternatives [10]. However, technique sensitivity, availability of appropriate donor teeth, and misconceptions regarding the postoperative outcome (such as root ankylosis) have precluded its routine use in clinical practice [35,10]. Kristerson and Andreasen revealed that root resorption becomes more prominent as root development progresses [36]. Mejare et al. (2004) reported a cumulative survival rate of 81.4% over a 4-year follow-up, while other studies have reported survival rates ranging from 71% to 95% after 1 to 3 years of follow-up [20,37, 11,12,38]. In a meta-analysis, Machado et al. (2016) reported survival rates of 75.3% to 91% for autotransplanted teeth during a follow-up period of 6 years or more [10]. In the same systematic review, ankylosis was reported in 4.2% to 18.2% of cases and root resorption in 3% to 10% of cases [10].

On the other hand, autotransplantation of mature third molars has been associated with a number of risks. Potential unfavorable outcomes, including pulp necrosis, pulp infection, and repair-related and infection-related root resorption have been frequently reported [11,12]. Another unfavorable outcome is pulp revascularization; this is not expected after transplantation of mature teeth, since the neurovascular bundle and periodontal fibers are ruptured during donor tooth extraction [11,12]. Considerable knowledge, surgical skill, patience, and care are needed to achieve a successful outcome. Failure is often related to recipient site conditions or difficulties removing the graft from the donor site. Success depends on postoperative healing of bone and soft tissue [11,12,36,39]. Favorable healing of the periodontal ligament depends on the number of viable cells preserved on the root surface of the donor tooth. Successful healing may be expected if donor teeth are extracted with minimal mechanical damage to the periodontal ligament [11,12, 36]. Trauma to the periodontal ligament and root surface induce resorption, which may affect the cementum and dentine. Ankylosis is a common type of root resorption where bone-forming cells begin attacking the root surface, and is caused by extended iatrogenic trauma to the donor root surface during transplantation

[38,40]. If and when transplanted teeth can be treated endodontically remains unanswered. In a 10-year comparative study, Yu et al. (2017) reported survival rates of third molar autotransplants with completely formed roots of 80.0%–95.2% [11]. However, only a few studies have reported long-term clinical success following autotransplantation of mature third molars [28,30,37, 11,12].

In this case series report, we describe our clinical experience of autologous tooth transplantation using mature and immature donor teeth into fresh extraction sockets in a small sample of young individuals. Aim of this clinical report is to evaluate: (i) the survival of autotransplanted donor teeth, and (ii) the success in terms of functionality, degree of mobility, periodontal status, and root and alveolar bone conditions over a mean follow-up period of 44 months.

## 2. CASE SERIES

### 2.1 Patient Collection

For this non-interventional observational retrospective case series report, we reviewed data of nine patients who were referred to our department of Oral and Plastic Maxillofacial Surgery at Ludwigshafen hospital in Germany between August 2013 and August 2018 for immediate tooth autotransplantation. Patients were recruited according to the following inclusion criteria: (1) 1–2 non-retainable teeth, chronic apical periodontitis, tooth agenesis in the posterior region, and ectopical canine eruption, (2) third molars with or without completely formed roots and a suitable shape and dimension for the recipient site after clinical and radiographic evaluation, (3) opposing dentition with natural teeth or a denture, (4) rejection of implant placement, and (5) minimum of 12 months follow-up post-transplantation. Participants were excluded (1) if the recipient site had insufficient bone volume, and (2) if poor oral hygiene was detected.

### 2.2 Data Collection

The study variables were obtained by reviewing patients' charts, anamnesis data, clinical and radiological findings, and surgical reports. The following preoperative and postoperative variables were analyzed:

- Demographic data (patient age and gender)

- Diagnosis of tooth pathology (e.g. caries, periodontal lesions, hypodontia, trauma etc.), and indication for surgery
- Localization of recipient site and alveolar bone status
- Localization of third molars, eruption status (unerupted, partially erupted, or fully erupted), and root development
- Surgical approach
- Surgical time from harvesting to transplantation
- Type of tooth fixation post-transplantation
- Time to fixation removal
- Postoperative complications (fixation looseness, wound dehiscence, neural alterations)
- Follow-up period (months)
- Clinical and radiological measures including vitality, mobility, functionality, root development, and alveolar bone development of transplanted teeth. Measurements were taken at 2 weeks and 6 months after transplantation, and once annually until the last follow-up visit (April 2020).

### 2.3 Treatment Plan

All surgical procedures were performed by two surgeons using standardized surgical techniques under local or general anesthesia depending on patient's age and extent of the procedure. Uncooperative patients under 18 years were operated under general anesthesia as well as patients receiving extended cystectomies and osteoplastic with bone from the iliac crest besides the tooth autotransplantation. Procedures involving tooth autotransplantation after extraction of one single tooth were performed under local anesthesia. Teeth were autotransplanted into fresh extraction sockets after appropriate preparation. In some cases, autologous cancellous bone was also grafted to guide bone regeneration.

### 2.4 Surgical Procedure

In order to determine the suitability of the donor tooth at the recipient alveolus, the length and diameter of the root(s) of the donor teeth were measured on the cross-sectional image of the cone beam computer tomography (CBCT) preoperatively. A horizontal tangent was drawn electronically using the measurement tool in Sirona software (Sirona Dental Systems Inc.) We pointed the most superior point and the most

inferior point of every root. The vertical height was then measured between these two tangents using the same measurement tool. The root diameter (mesio-distal dimension) was measured after defining two horizontal points at the third middle of the root. The same protocol was carried out to record the root dimensions of the tooth at the recipient bone alveolus prior to extraction. All measurements throughout were made by the same two surgeons.

The non-retainable molar was extracted as atraumatically as possible, and interradicular bone at the recipient site was removed using a conventional rotary drill to create an appropriate four-walled socket. This was performed under continuous sterile saline irrigation to avoid thermal damage to bone at the recipient site. When periapical infection was detected at the recipient site, thorough curettage was carried out to remove infected tissue. Saline-soaked gauze was placed at the recipient site until the donor molar was harvested. If the third molar was completely erupted, it was extracted atraumatically using an elevator. To remove impacted third molars, osteotomy was carried out following full-thickness flap reflection, using rotary drills for minimal surgical trauma. In one case, a maxillary second molar was used as the donor, and in another case, an impacted unerupted maxillary canine was surgically transferred to its appropriate position in the dentition. In all cases, care was taken to preserve the periodontal ligament attached to the root. The donor tooth was placed at the recipient site as quickly as possible; the average duration between removal and transplantation of the donor tooth was 15 min. In cases when the donor tooth did not fit exactly to the dimensions of the recipient alveolus, the intraalveolar bone was extra modified using a rotary drill for the donor roots to fit in the new recipient alveolus in their dimension as exactly as possible and without extended pressure to the surrounding bone. During this procedure, the donor tooth was preserved in a gauze pack dipped in physiologic saline solution until the recipient site was ready. If the crown of the donor tooth interfered with its placement in the recipient site, the mesial and distal surfaces were ground down by 0.5 mm using a rotary drill. After positioning into the recipient site, mild occlusal pressure was applied to achieve stability at the new position. No endodontic treatment was performed in any patients during transplantation.

## 2.5 Fixation of the Autotransplanted Tooth

The enamel on the buccal surface of the autotransplanted donor tooth and two adjacent teeth (mesially and distally) was etched with 37% phosphoric acid for 30 sec. Adhesive was then applied to and a stainless steel wire was fixed on the etched enamel of the three teeth with light-cured composite resin. The soft tissues were stabilized using 4/0 resorbable sutures, tightly adapting the gingiva around the tooth. Any premature occlusal contacts were eliminated and the configuration of the transplanted teeth was then adjusted in accordance with the contralateral teeth. The surgeon ensured with an articulating paper, that the transplanted teeth were out of occlusion.

## 2.6 Postoperative Care

Antibiotics (amoxicillin, 500 mg three times daily for 3 days) were prescribed for 5 days together with appropriate analgesics. Patients were instructed to stick to a semisolid diet to avoid mastication and to rinse with 0.12% chlorhexidine for 30 sec three times a day for at least 3 weeks. Sutures were removed after 10 days, and the splint was removed after 2 weeks to avoid ankylosis.

## 2.7 Follow-up

Patients were followed-up until April 2020. Patients were recalled at 2 weeks and 6 months after transplantation, and annually thereafter until the last follow-up visit. Follow-up clinical examinations were made by different clinicians.

## 2.8 Clinical Evaluation

Patients were monitored for signs of soft tissue infection such as swelling, abscess, and altered percussion. Periodontal probing was carried out to evaluate the pocket depth at four locations (mesiobuccal, distobuccal, mesiolingual, and distolingual) around the transplant. A probing depth of > 3 mm was defined as pathologic. Mobility of the tooth was graded as: 0 = no abnormal mobility; 1 = horizontal mobility of ≤ 1 mm; 2 = abnormal horizontal mobility of > 1 mm; and 3 = abnormal horizontal mobility of > 1 mm with axial mobility. A pulp cold sensitivity test was carried out to evaluate the pulp status. A high, metallic percussion sound indicated ankylosis and unfavorable healing. Pain caused by the percussion indicated further clinical observation prior to endodontic treatment.

## 2.9 Radiological Evaluation

Panoramic radiographs were obtained before transplantation, at time of fixation removal 2 weeks after surgery, and 6 months after transplantation. Because our patients were young, further radiographs were only indicated in cases of pathology needing further clarification. The aim was to monitor root development and the periodontal condition before transplantation and during healing. A continuous periodontal ligament space and intact lamina dura surrounding the entire root periphery was defined as eventful periodontal healing of the transplanted tooth. Radiographic presence of root resorption and periapical radiolucency in terms of infection-related alveolar resorption indicated insufficient healing.

## 2.10 Criteria to Record a Final Outcome of the Autotransplantation

### 2.10.1 Success

The transplanted tooth was deemed successful if it fulfilled the following criteria at the end of the follow-up period: (1) functioning normally without physiologic mobility; (2) no discomfort on periodontal probing and pockets of no more than 3 mm; and (3) no root resorption and normal alveolar bone process (absence of periapical radiolucency).

### 2.10.2 Survival

Survival was defined as presence of transplanted tooth in its transplanted localization at the final follow-up visit (April 2020). The survival time was defined as the number of months from transplantation to the time of final follow-up or to the date on which the transplant was removed.

## 2.11 Data Analysis

Demographic data, indication for surgery, donor and recipient site, and follow-up findings were entered in Microsoft Excel 2010 and were presented descriptively. Descriptive statistics including means and ranges were computed. Percentages were also calculated and presented in a table.

## 2.12 Case 1

A 19-year-old Caucasian female patient was referred to our clinic with pain and a decayed maxillary first right molar. Clinical examination

showed an extended caries lesion with a negative cold pulp test result and a painful reaction to percussion. Grade 1 mobility was also observed. An orthopantomogramm detected a periapical osteolysis on tooth 16 and unerupted third molars in all four quadrants (Fig. 1A). After evaluating the bone quality at the recipient site and conditions of possible donor teeth, possible treatments to prevent local alveolar bone resorption were explained to the patient, including an autologous tooth transplantation, conventional bridge restoration or single dental implantation, was suggested and explained to the patient. Autologous tooth transplantation was performed as described above and the maxillary right third molar (tooth#18) was transplanted into the fresh extraction socket in region 16 (Fig. 1B). At the 6-month follow-up, no pathology of the autotransplanted tooth was detected. The pulp cold sensitivity test was negative. Periodontal pockets of no more than 3 mm, a normal percussion sound, and physiological mobility were also observed. Follow-up examinations were conducted until 78 months after autotransplantation. No root resorption and eventful alveolar bone remodeling was determined by radiography. At the last follow-up in April 2020, the donor tooth was still in its transplanted position, indicating successful treatment.

### 2.13 Case 2

The patient was a 17-year-old Caucasian male, referred to us with pain in the right posterior maxilla. Clinical examination showed an extended caries lesion of the second premolar and the first molar (teeth#15/16) with a negative cold pulp test result and painful reaction to percussion. No clinical signs of abscess were detected. Both teeth showed grade 1 mobility. An initial panoramic radiograph detected insufficient root canal fill at both teeth, followed by periapical osteolysis. Unerupted immature third molars were also detected in the second, third, and fourth quadrant (Fig. 2A). Because the patient was young, we suggested extracting both teeth and replacing them with the third molars of the second and third quadrant to prevent local bone resorption. This was a typical indication for tooth autotransplantation, in that no endodontic and restorative treatments were suitable. Implant prosthesis in region 15/16 after the age of 18 years could be a rational alternative, since a conventional bridge restoration involving the teeth 14 and 17 is in absence of caries contraindicated. During transplantation, the

periapical infection at the recipient site was curetted to remove infected tissue and the third molars were transplanted as described above (Fig. 2B). At the 2-week follow-up, extended root resorption of both transplanted teeth and uneventful alveolar bone remodeling periapically were detected (Fig. 2C). We decided to leave the fixation for longer to avoid increased mobility and early tooth loss. The wire fixation was still in place 5 months later. The pulp cold sensitivity test was negative. Periodontal pockets of no more than 3 mm, grade 1 mobility, and no pain were observed. In the absence of symptoms, no endodontic treatment was recommended. Periapically, no alveolar bone remodeling had taken place and root resorption had progressed (Fig. 2D). Clinical follow-ups were conducted for 77 months after autotransplantation. At the final follow-up appointment in April 2020, the donor teeth were still in their transplanted position, but grade 1 mobility and extended root resorption were detected radiographically.

### 2.14 Case 3

The patient was a 25-year-old female with pain in the mandibular left first molar, caused by severe caries. An initial orthopantomogramm showed an insufficient root canal fill and extended periapical osteolysis in region 36, so extraction of the tooth was indicated (Fig. 3A). The mandibular right third molar with completely formed roots was considered an ideal donor tooth for autologous tooth transplantation (Fig. 3B). Single implantation in region 36 could be a therapeutic alternative, since a conventional bridge restoration involving the healthy teeth 35 and 37 is contraindicated. At the 6-month follow-up, results of the pulp cold sensitivity test and percussion test were negative, periodontal pockets were normal, and physiologic mobility of the autotransplanted third molar was detected. However, radiographic evaluations revealed progressive root resorption (especially of the mesial root) and alveolar bone remodeling at the 3-year-, 3.5-year-, and 5-year follow-up (Fig. 3C–F). Follow-up was conducted for 69 months after autotransplantation. At the final follow-up appointment in April 2020, the transplanted tooth was still in place, showing physiological mobility and satisfied masticary function.

### 2.15 Case 4

A 12-year-old male patient was referred to our clinic with an ectopically impacted, maxillary left canine and an extended radicular cyst in the left

maxilla (Fig. 4A). Cystectomy and local augmentation with autologous cancellous bone from the iliac crest were indicated. The ectopic impacted canine was replaced and stabilized into the extraction socket of the deciduous maxillary left canine in an appropriate occlusal position as described above (Fig. 4B). As alternative therapy would be an implant prosthesis after uneventful wound healing in region 23; however, not indicated in this case because of the young age of the patient. At the 6-month follow-up, results of the pulp cold sensitivity test were negative and there were no pathological findings. A radiograph at 6 months after surgery showed resolution of the previous large bony defect, consistent with successful healing and bone regeneration around the transplanted canine (Fig. 4C). To date, 25 months after surgery, the patient is on orthodontic treatment and the transplanted tooth has satisfactory physiological mobility and masticatory function.

### 2.16 Case 5

A 14-year-old female patient was referred to us with agenesis of the mandibular second premolars. The maxillary left second molar had an unfavorable prognosis because of severe periodontitis. A radiograph revealed a large bony defect, and grade 2 mobility was observed (Fig. 5A). At that time, the maxillary third molars were minimally developed and no mandibular sperms were observed, so there was no third molar as a donor (Fig. 5A). A single implantation in region 35 could be a feasible alternative since the teeth 34 and 36 did not have signs of caries; however, this alternative was contraindicated because of the young age of the patient. After explaining the therapy protocol, the maxillary left second molar was transplanted into region 35 after extraction of the mandibular second deciduous molar (tooth#75) and appropriate surgical preparation of the extraction socket. Sixteen months later, the transplant showed clinical signs of inflammation. Results of the cold pulp test were negative, mobility was grade 2, and periodontal sockets were 5 mm mesially and lingually. Extended root resorption and uneventful bone regeneration around the transplant were clearly observed by radiography (Fig. 5B). Despite endodontic treatment from the referring dentist, the transplanted molar was extracted almost 2 years after surgery.

### 2.17 Case 6

A 17-year-old male patient presented with extensive composite restorations and apical

osteolysis of both mandibular first molars (Fig. 6A). Both teeth were erupted ectopically on the lingual aspect of the mandible, making local hygiene difficult. After multiple tooth crown restorations, the patient was looking for alternative long-term solutions besides the conventional bridge restorations. Dental implantation was not indicated because the patient was young, and the patient did not want another prosthetical crown; therefore, autotransplantation of the immature mandibular third molar was recommended to the patient. The left lower third molar was transplanted into the extraction socket of tooth 36 and the right lower third molar was transplanted into region 46 (Fig. 6 B–C). At the 6-month follow-up, both transplanted teeth were in situ with no mobility or other pathological findings. Results of the pulp cold sensitivity test were negative and the percussion sound was normal. Radiography revealed complete root development, although without alveolar bone remodeling at that time (Fig. 6D). Follow-ups were conducted every 6 months for 30 months. At the final follow-up in April 2020, the transplanted teeth were still in situ, showing physiological mobility and satisfactory masticatory function.

### 2.18 Case 7

The mandibular left first molar of a 20-year-old female patient had an unfavorable prognosis because of extended intraradicular osteolysis and recurrent fistula on the buccal site (Fig. 7A). Since a single implantation in region 36 was not wished by the patient as a rational alternative, we decided for the autotransplantation of the mature mandibular left third molar. The tooth 36 was then replaced with the tooth 38 under local anesthesia (Fig. 7B). Six months after transplantation, eventual bone regeneration without root resorption was observed radiographically (Fig. 7C). The transplanted tooth was followed up for 26 months until April 2020, and no complications were observed.

### 2.19 Case 8

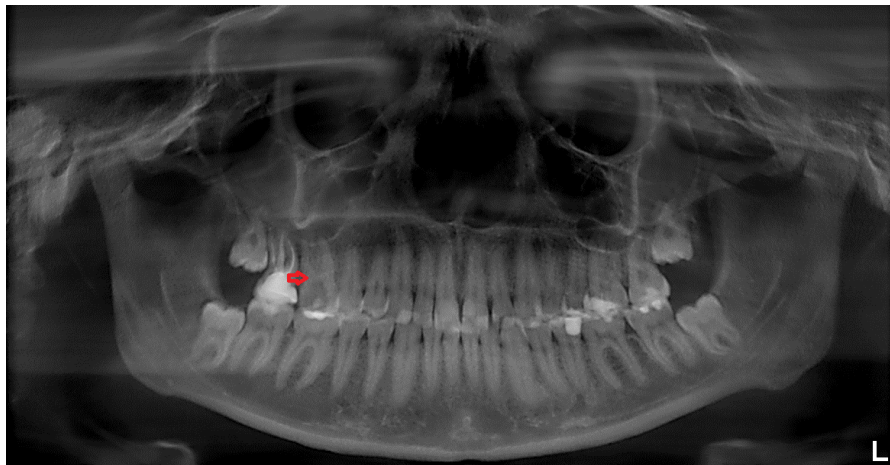
The patient was a 20-year-old male with resistant pain on the mandibular left first molar. The tooth was damaged by caries, but no abscess was observed (Fig. 8A). Tooth extraction and third molar autotransplantation was indicated, since single implantation was not wished and a conventional bridge restoration involving the teeth 35 and 37 not indicated. The mandibular left third molar with completely formed roots was considered an ideal transplant donor (Fig. 8B). At

the 6-month follow-up, no pathological clinical findings of the autotransplanted third molar were detected. To date, 20 months after surgery, the transplanted third molar is still in situ, indicating successful treatment.

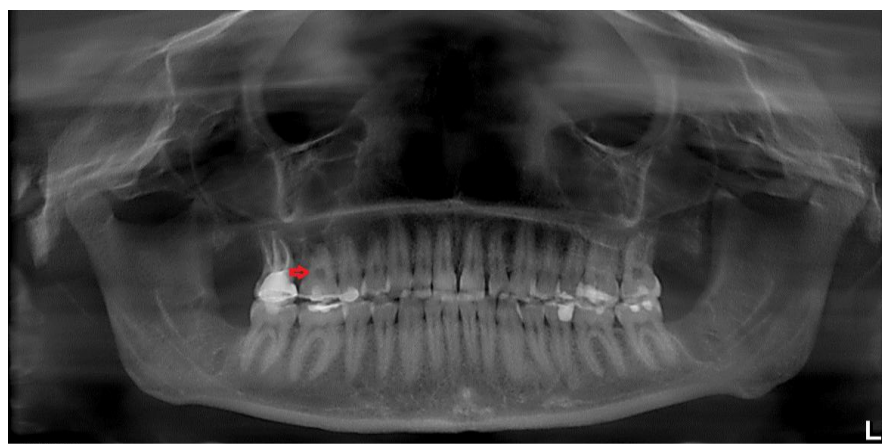
## 2.20 Case 9

Autologous tooth transplantation is a non-typical indication in cases of accidental tooth extractions. This occurred in a 16-year-old male patient who was referred to our clinic for surgical removal of all four unerupted third molars (Fig. 9A). Unfortunately, the mandibular right second molar (tooth#47) was damaged with cutting burs during osteotomy because of the extended infraocclusal and mesioangular position of the mandibular right third molar. The damage was non-restorable, so the tooth had to be extracted.

After informing the patient of the tooth damage, the immature third molar from the same quadrant was transplanted into the extraction socket (region 47) and stabilized with stainless steel wire and light-cured composite resin (Fig. 9B). The patient was informed about the procedure risks and possible survival of the transplanted tooth. An alternative solution could be an implantation in region 47 after uneventful wound healing. The case was followed-up for 3.5 years, and no clinical abnormalities were observed. A panoramic radiograph at 6 months post-transplantation showed normal development of the mesial and distal root and an eventful periodontal healing process (Fig. 9C). At the final follow-up in April 2020, the transplanted tooth was still in situ with physiological mobility and satisfactory masticatory function. No endodontic treatment was needed to date.

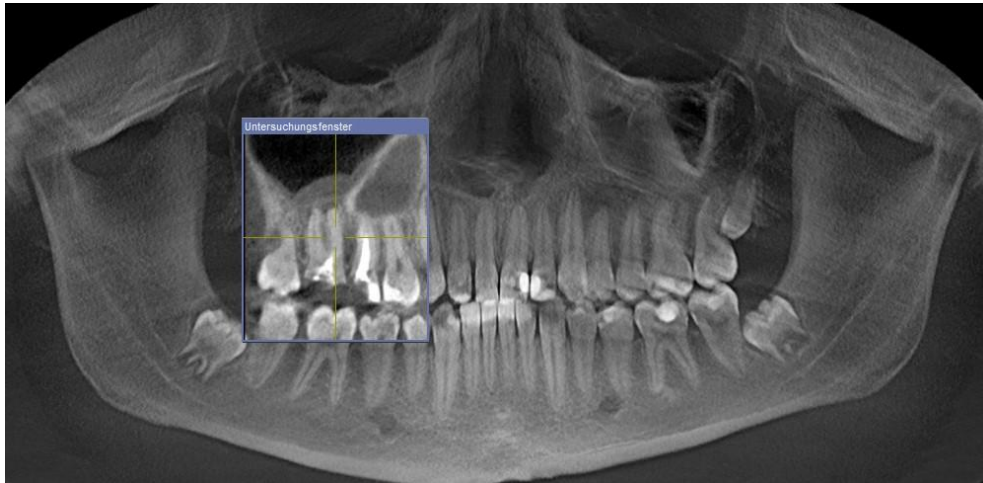


**Fig. 1A. Preoperative panoramic radiograph showing extended caries lesion on the maxillary right first molar (recipient site) and a mesioangular unerupted third molar (donor site) in the same quadrant**

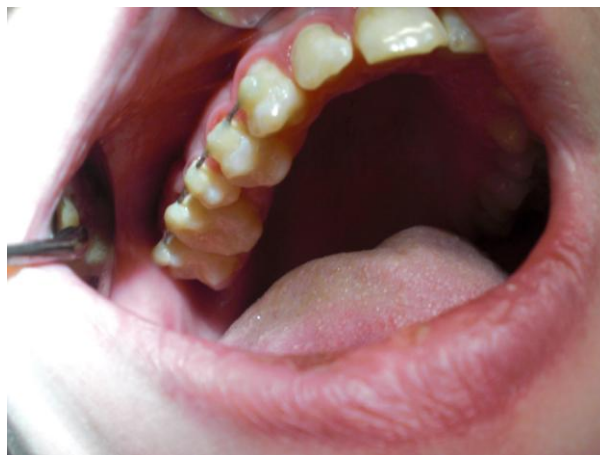

**Fig. 1B. Postoperative panoramic radiograph obtained 2 weeks after surgery showing the transplanted third molar (tooth#18) placed in the prepared receptor alveolus (region 16) and stabilized with stainless steel wire and light-cured composite resin**

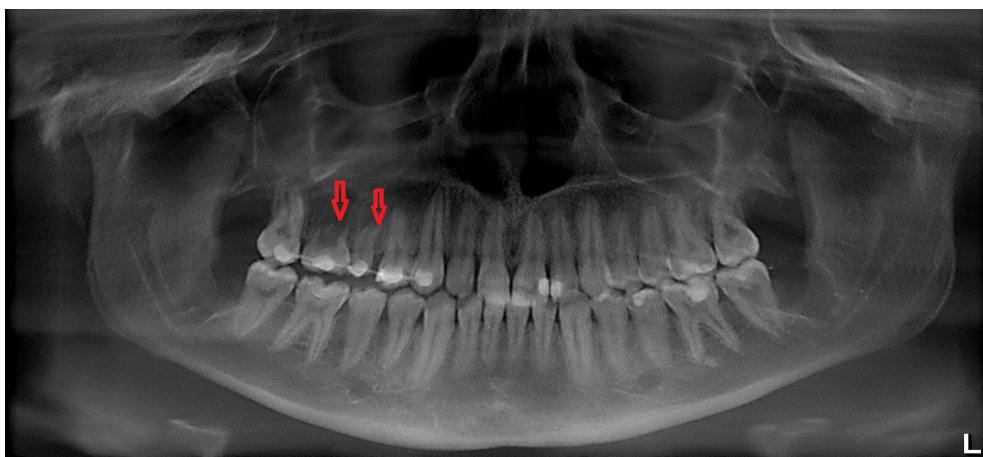




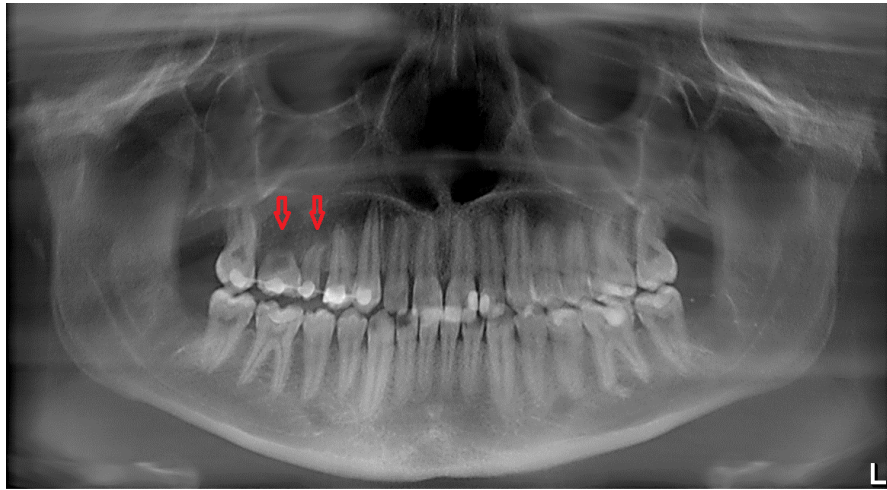
**Fig. 2A.** Preoperative cone beam computer tomography showing insufficient root canal treatment of teeth#15/16 and a periapical radiolucency extended to the sinus maxillaris floor in terms of periapical cyst. The mesioangular unerupted third molars 28/38/48 with incomplete root formation are also presented



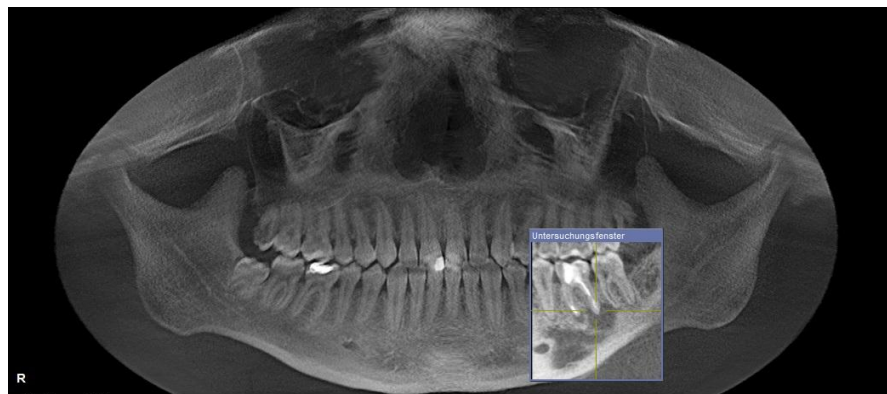
**Fig. 2B.** Intraoperative view of the transplanted third molars in the maxillary right posterior side fixed with stainless steel wire and light-cured composite resin



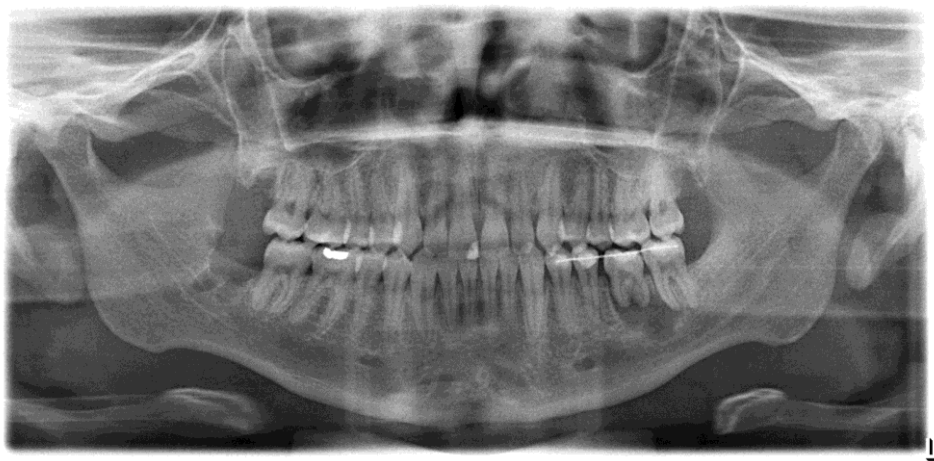**Fig. 2C.** Postoperative panoramic radiograph obtained 2 weeks after surgery showing the donor third molars transplanted and stabilized into the recipient sockets (region 15/16)



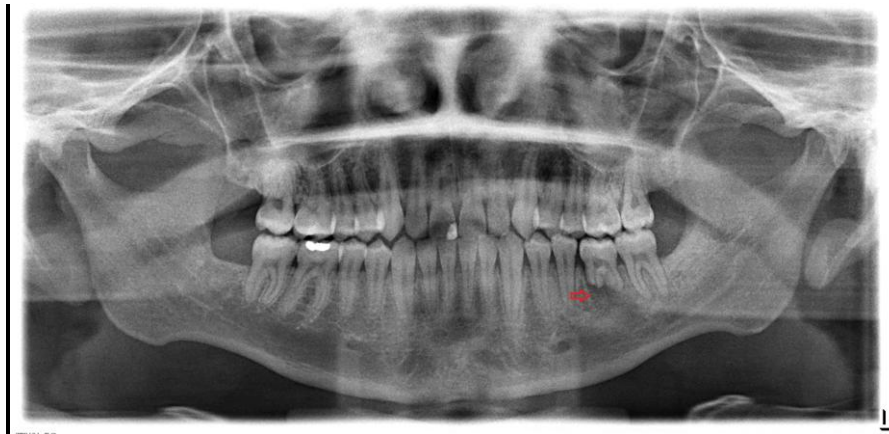**Fig. 2D.** Panoramic radiograph at 6 months postoperatively showing extended root resorption of both transplanted teeth and absence of alveolar bone regeneration



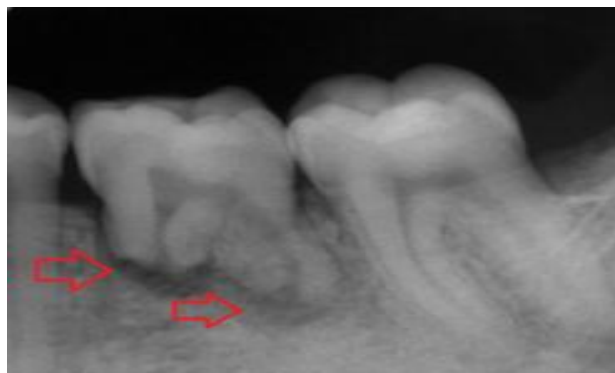**Fig. 3A.** Preoperative panoramic radiograph showing insufficient root canal treatment and periapical osteolysis of the mandibular left first molar (red arrow). After extraction, the mesioangular unerupted mature mandibular right third molar was transplanted into the prepared recipient alveolus.



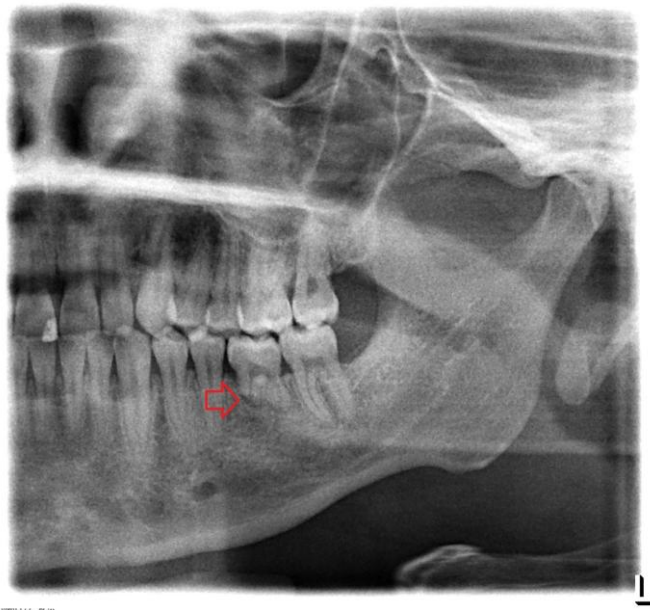**Fig. 3B.** Postoperative panoramic radiograph obtained 2 weeks after surgery showing the transplanted donor third molar stabilized into the recipient socket (region 36)



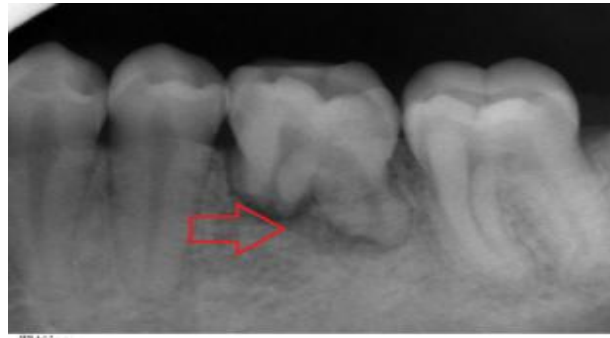**Fig. 3C. Postoperative panoramic radiograph at 6 months post-transplantation presenting extended root resorption (red arrow)**



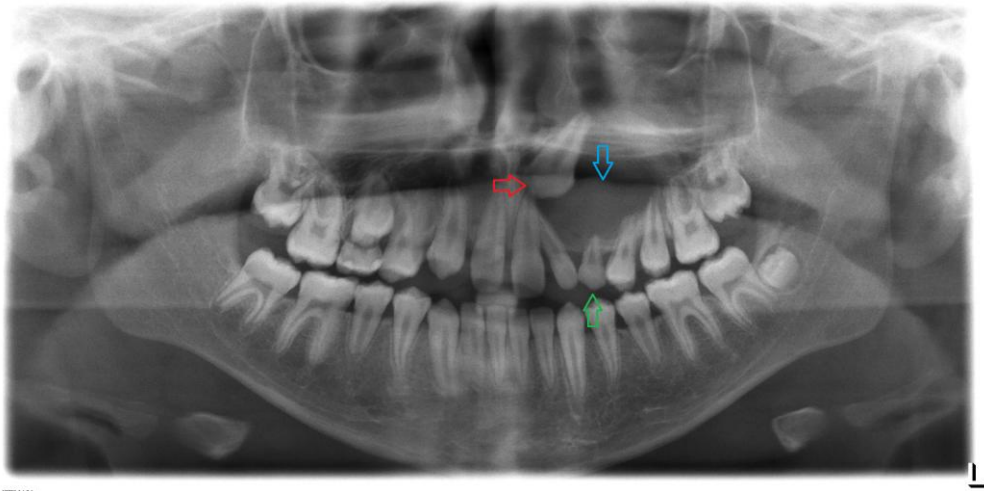
**Fig. 3D. Radiograph 3 years post-transplantation presenting extended resorption of the mesial root and an eventual alveolar bone regeneration (red arrows)**



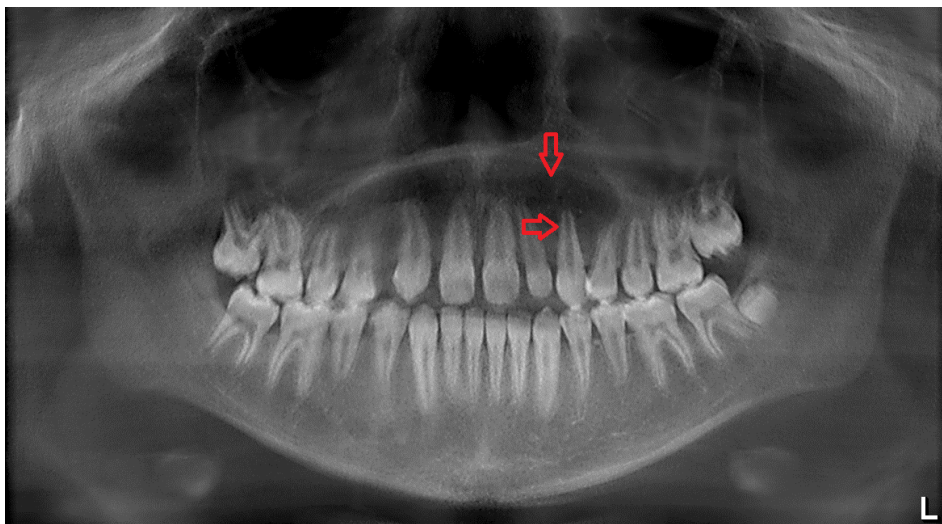
**Fig. 3E. Panoramic radiograph at 3.5 years post-transplantation showing progressive alveolar bone remodeling (red arrow)**



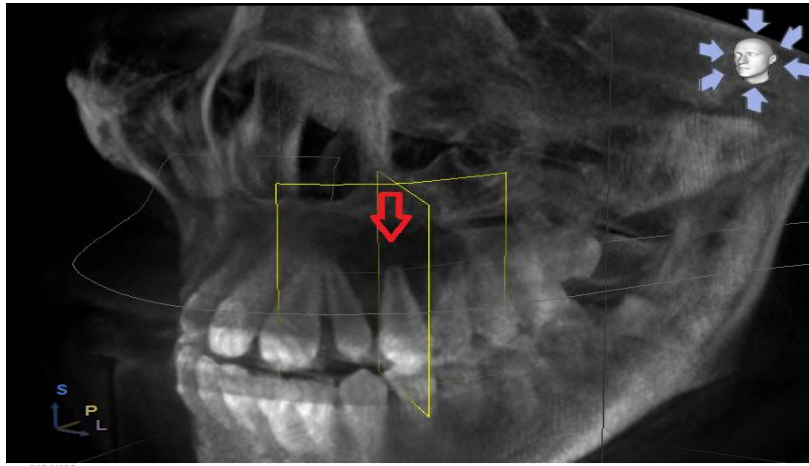
**Fig. 3F.** Radiograph at 5 years post-transplantation. The alveolar bone remodeling process is almost completed (red arrow)



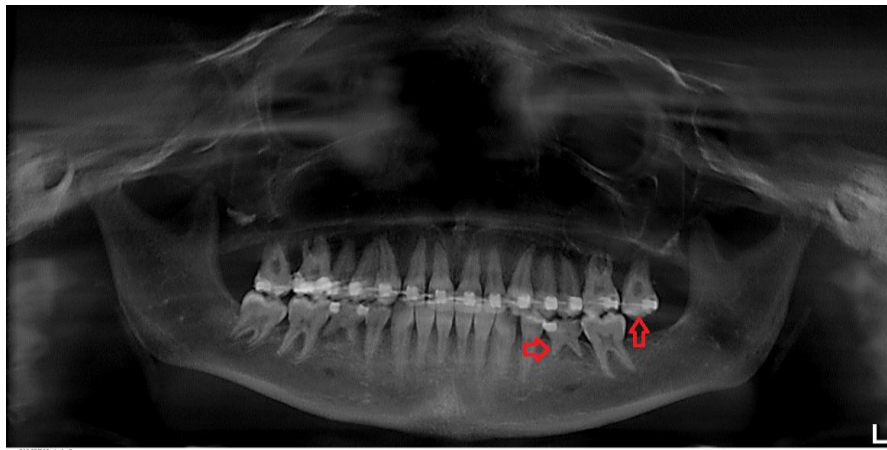
**Fig. 4A.** Initial panoramic radiograph showing an extended radicular cyst in the left maxilla (blue arrow); The persistent deciduous canine (green arrow) was removed and the ectopic impacted canine (red arrow) was transplanted into the fresh extraction socket



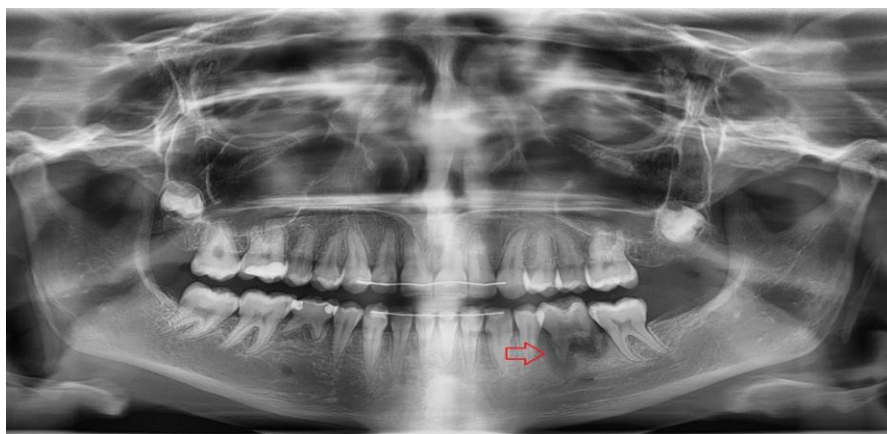**Fig. 4B.** Panoramic radiograph at 2 weeks post-transplantation after fixation removal. Appropriate occlusal position of the transplanted canine in the maxilla and decrease of the cyst's size are observed (red arrows)



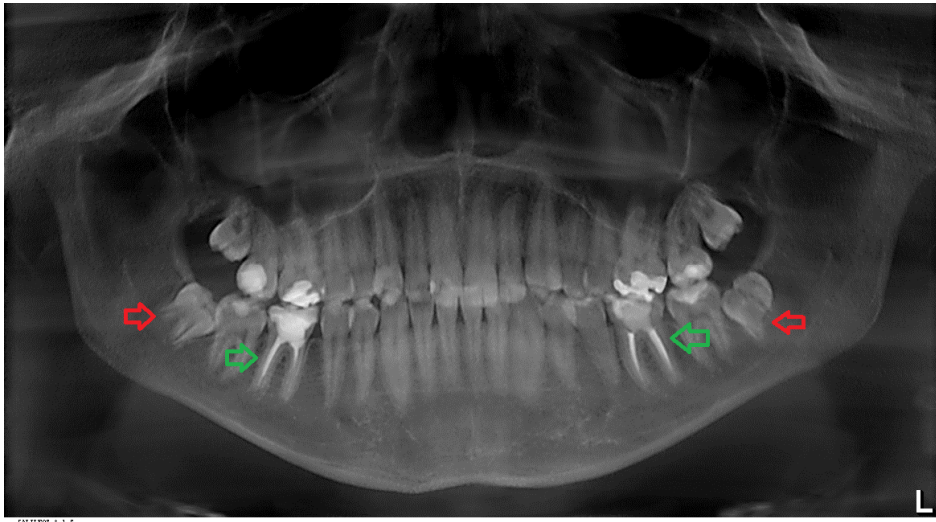
**Fig. 4C. Lateral view of the maxilla in a cone beam computer tomography at 6 months postoperatively showing the almost complete root development of the transplanted canine (red arrow)**



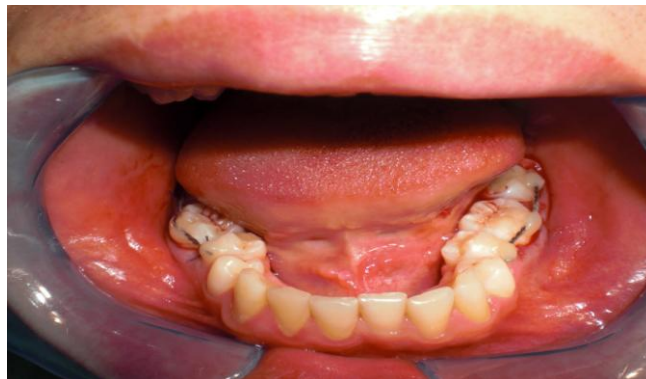**Fig. 5A. Initial panoramic radiograph showing agenesis of the mandibular second premolars, permanence of the lower second deciduous molars and a periodontally damaged upper left second molar (red arrows)**



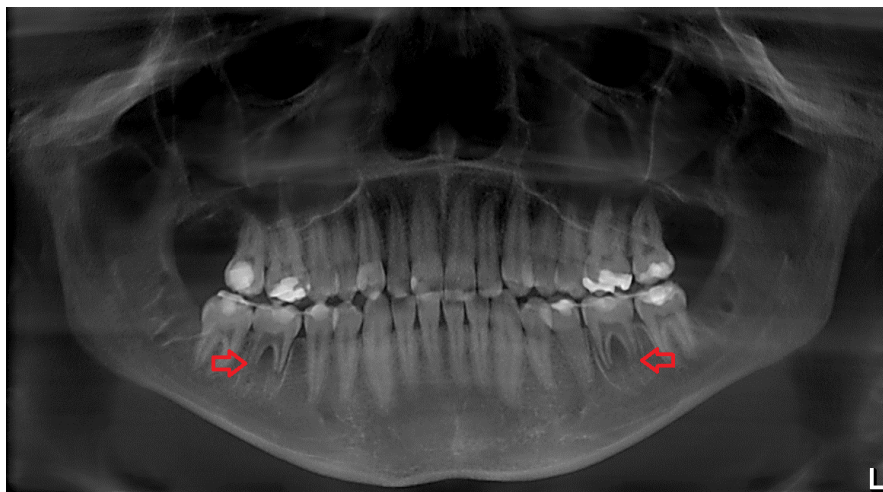
**Fig. 5B. Follow-up radiograph at 14 months post-transplantation; Uneventful bone regeneration and extended root resorption are detected (red arrow). The transplanted tooth was extracted few months later**



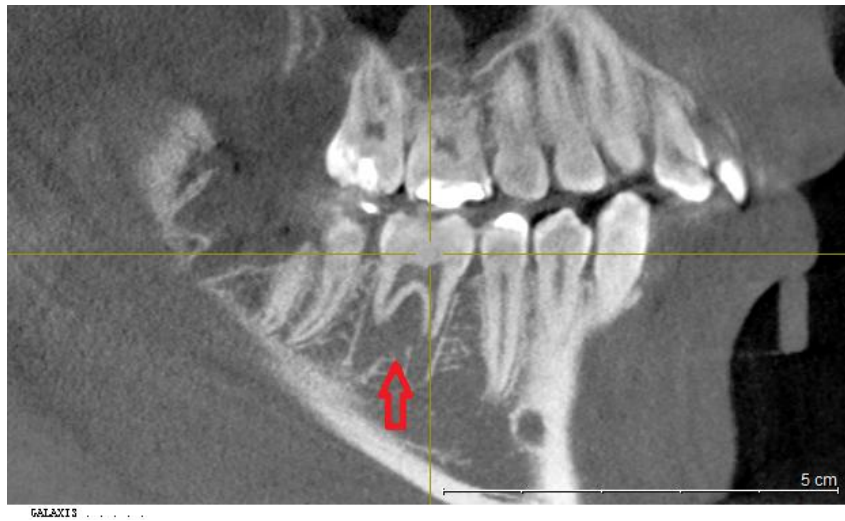
**Fig. 6A. Initial panoramic radiograph. Green arrows show the extended crown restorations and insufficient root canal fills of the mandibular first molars; red arrows show the immature impacted lower third molars**



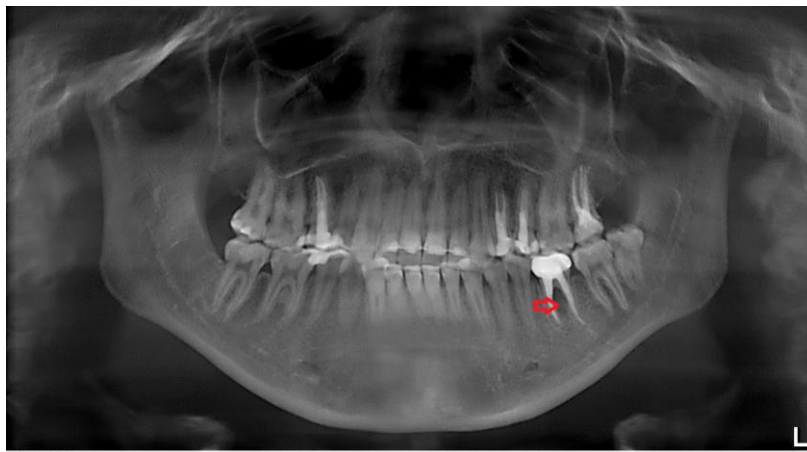
**Fig. 6B. Intraoperative clinical view after autologous transplantation of the donor third molars and fixation in the prepared recipient sockets (region 36/46)**



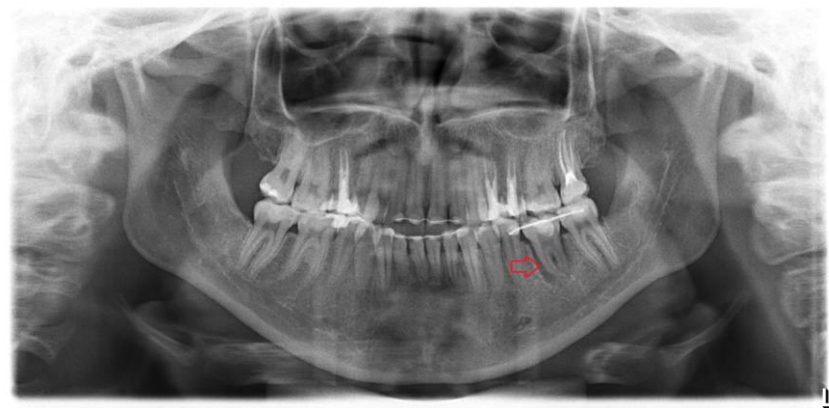
**Fig. 6C. Panoramic radiograph at 2 weeks post-transplantation; The size of extraction sockets in region 36 and 46 is larger than that of the transplanted immature third molars.**



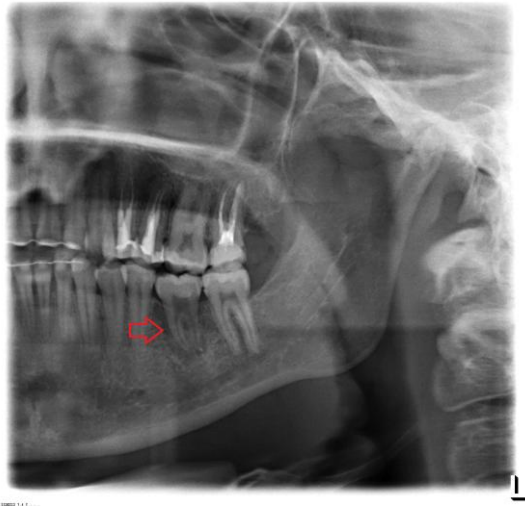
**Fig. 6D.** Postoperative radiograph at 6 months after transplantation; Complete root development and progressive bone remodeling are observed (red arrow)



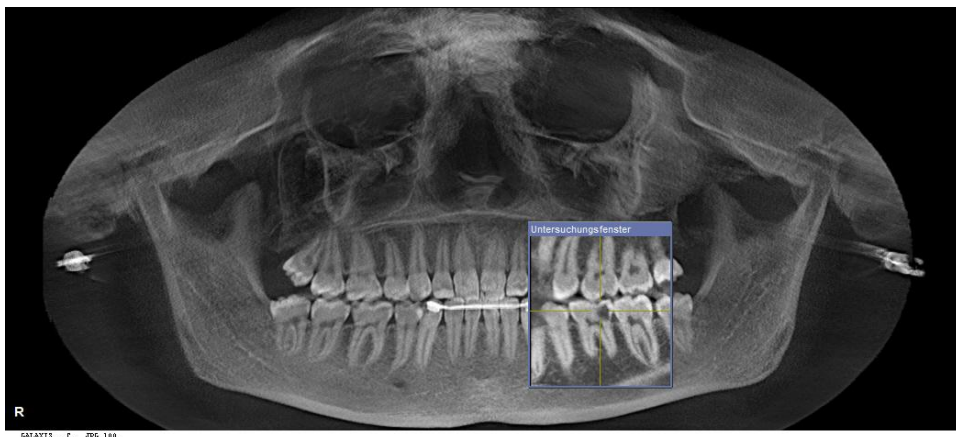
**Fig. 7A.** Initial panoramic radiograph; The semi-erupted mature mandibular left third molars would replace the poor prognosed mandibular left first molar (red arrow)



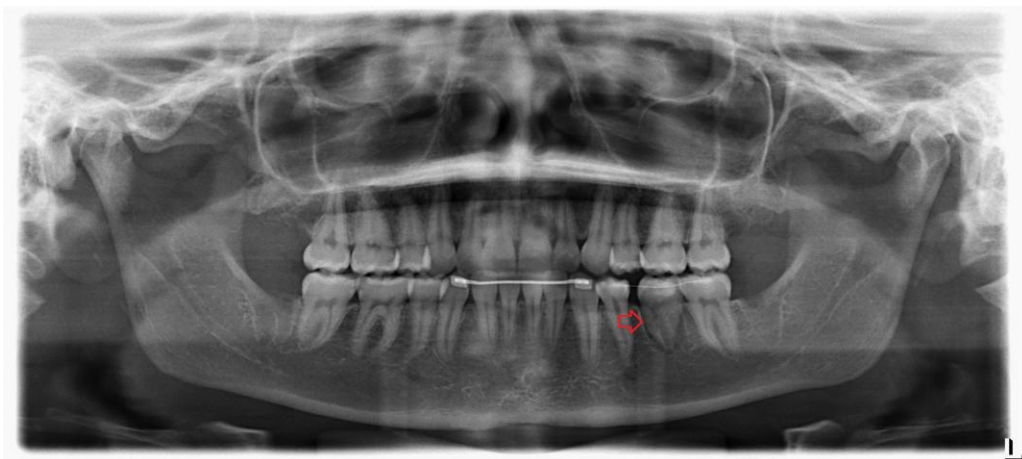
**Fig. 7B.** Panoramic radiograph at 2 weeks after autotransplantation showing satisfied fitting of the donor third molar into the prepared recipient socket of the extracted mandibular left first molar (red arrow)



**Fig. 7C. Successful bone regeneration and appropriate occlusal adaptation of the transplanted third molar; No root resorption detected (red arrow)**

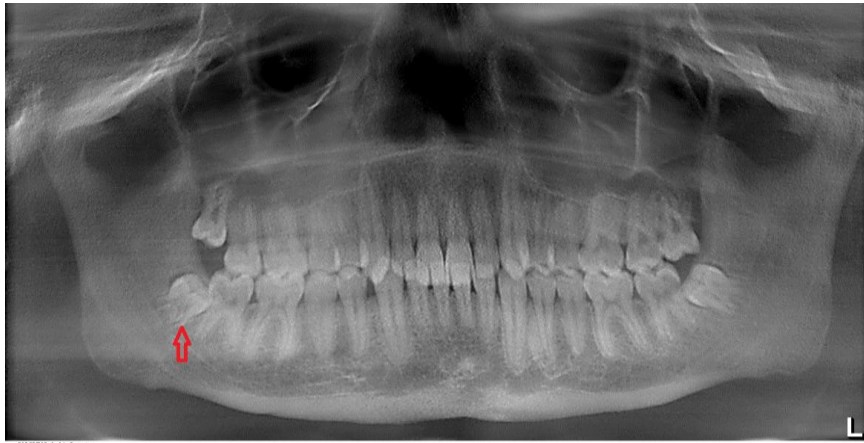

**Fig. 8A. Initial panoramic radiograph showing extended carious lesion of the mandibular left first molar and semi-erupted third molars in all four quadrants**

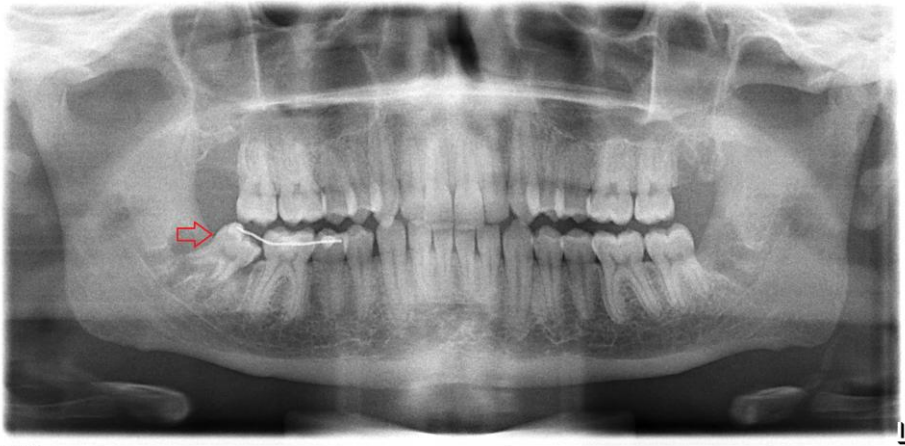

**Fig. 8B. Panoramic radiograph at 2 weeks after autotransplantation showing the donor mandibular left third molar fixed in his new position (recipient region 36). Eventful alveolar bone remodeling without root resorption is detected (red arrow)**

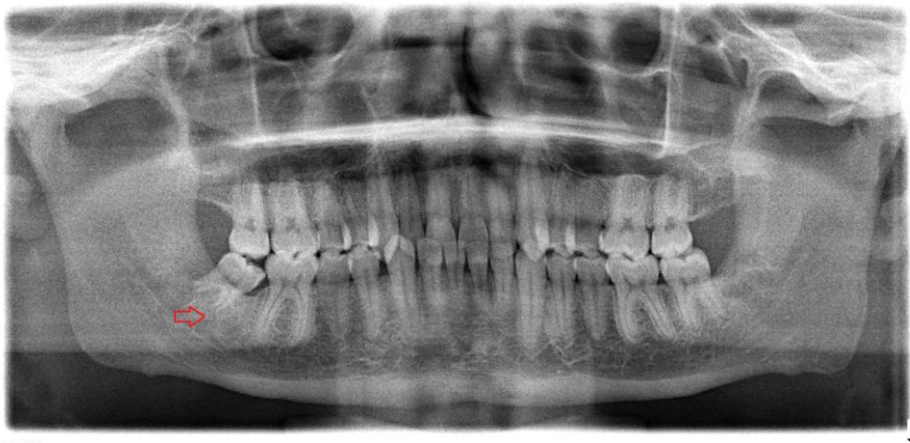



**Fig. 9A.** Initial panoramic radiograph showing a normal dentition and four impacted third molars; The mandibular right third molar appears in an extended infraocclusal mesioangular position (red arrow)



**Fig. 9B.** Postoperative panoramic radiograph obtained directly postoperatively showing the transplanted donor third molar fixed in the recipient socket of the mandibular second molar after its iatrogenic trauma and extraction followed (red arrow)



**Fig. 9C.** Follow-up at 6 months post-transplantation presenting a normal root development and completed periapical bone remodeling (red arrow)

### 3. RESULTS

#### 3.1 Patient Characteristics

The present report included nine consecutive patients (six males, three females), with a mean age of 18.34 years (range: 12 to 25 years), who were treated from 2013 until 2018 in our craniomaxillofacial clinic. In each of these patients, a tooth (a molar in most cases) was autotransplanted with either completely or incompletely formed roots following a clinical and radiographic evaluation. Six patients were operated under general anesthesia and three under local anesthesia.

#### 3.2 Diagnosis / Indication for Autotransplantation

The reasons for autologous tooth transplantation were chronic apical periodontitis (n = 5 teeth), non-restorable extended caries (n = 3 teeth), ectopic canine impaction (n = 1 tooth), hypodontia (n = 1 tooth), and accidental trauma (n = 1 tooth).

#### 3.3 Transplanted Teeth

A total of 11 autogenous tooth transplantations were carried out in nine patients during the study period. Overall, nine third molars, one second molar, and one canine were autotransplanted. Mandibular third molars were donor teeth in seven cases (63.6%), maxillary third molars in two cases (18.1%), one maxillary second molar in one case (9.1%), and one maxillary unerupted canine in one case (9.1%). Six of the donor teeth had completely formed roots and five had incompletely formed roots with an open apex at the time of surgery. All donor teeth were immediately transplanted into freshly prepared recipient sites after tooth extraction. The replaced teeth included six mandibular molars, two maxillary molars, one mandibular premolar, one maxillary premolar, and one maxillary canine.

#### 3.4 Follow-up

Follow-up was terminated in April 2020. The follow-up period ranged from 20 to 78 months (mean: 44 months). No patients were lost to follow-up. The patients were evaluated clinically at 2 weeks, 6 months, and 12 months after surgery, and annually thereafter. Radiographic examinations were carried out at 2 weeks and 6 months post-transplantation. Cold pulp vitality

test results were negative in all transplanted teeth during the observation period, indicating negative pulp revascularization in all transplanted teeth, regardless of root development at the time of surgery. Root resorption was recorded for four out of 11 (36.3%) autotransplanted teeth. No endodontic treatment was carried out in the five successful cases using donor teeth with complete root formation at the time of transplantation.

#### 3.5 Success and Survival Rate

Seven cases (63.6%) were successful (according to our criteria), and four cases (36.4%) were unsuccessful. In these four cases, root resorption and uneventful alveolar bone regeneration were detected. Three of the unsuccessfully transplanted teeth were still in place without clinical symptoms at the final follow-up. The transplanted maxillary left second molar (case 5) was extracted 2 years after surgery because of infection-related root resorption and absence of periapical alveolar generation. None of the successful cases with incomplete root formation showed positive cold pulp test results during follow-up. The final autotransplant survival rate was 90.9% and the final autotransplant success rate was 63.6%.

Demographic data, indications for tooth autotransplantation, number and distribution of transplanted teeth, recipient sites, and follow-up findings are presented in Table 1.

### 4. DISCUSSION

Dental rehabilitation of missing teeth can be achieved with several methods, including removable or fixed prostheses, osseointegrated implants, or autotransplantation. In the early 1950s, tooth autotransplantation was introduced to replace decayed first molars with impacted immature third molars, but the success rate was low at that time [1,2,41]. Technological improvements over the last decades have made autologous tooth transplantation a more predictable treatment option in modern dentistry [6,7,8,9,21,22,13,14,10,11,12].

Replacement of congenitally missing teeth and teeth with an unfavorable tooth prognosis with tooth transplants has several advantages over implants in terms of function, esthetics, time, and cost, but only if an appropriate donor tooth can be preserved. However, preparing healthy teeth to support fixed partial dentures presents

**Table 1. Demographic data, indications for tooth autotransplantation, number and distribution of transplanted teeth, recipient sites, and follow-up findings**

Patient number	Age (year)/ Gender	Diagnosis / Indication for transplantation	Donor tooth type	Recipient site	Transplantation region	Periapical infection (recipient site)	Root development of donor tooth	Follow-up (months)	Root resorption	Transplanted tooth in situ at final recall (April 2020)
1	18/Female	chronic apical parodontitis	maxillary third molar	right maxilla posterior	18-->16	present	complete	78	no	yes
2	17/Male	chronic apical parodontitis	maxillary third molar	right maxilla posterior	28-->15	present	incomplete	77	yes	yes
			mandibular third molar	right maxilla posterior	38-->16	present	incomplete	77	yes	yes
3	25/Male	chronic apical parodontitis	mandibular third molar	left mandible posterior	48-->36	present	complete	69	yes	yes
4	12/Male	ectopical impactation	maxillary canine	left maxilla anterior	23-->23(63)	present	incomplete	25	no	yes
5	14/Female	hypodontia	maxillary second molar	left mandible posterior	27-->75(35)	absent	complete	29	yes	no
6	17/Male	extended caries	mandibular third molar	left mandible posterior	38-->36	absent	incomplete	30	no	yes
			mandibular third molar	right mandible posterior	48-->46	absent	incomplete	30	no	yes
7	20/Female	chronic apical parodontitis	mandibular third molar	left mandible posterior	38-->36	present	complete	26	no	yes
8	20/Male	extended caries	mandibular third molar	left mandible posterior	38-->36	absent	complete	20	no	yes
9	16/Male	akzidentell	mandibular third molar	right mandible posterior	48-->47	absent	incomplete	42	no	yes

potential aesthetic and functional problems. Autotransplants can provide superior esthetic results because they maintain the natural profile, and natural color and form of the enamel. Autotransplantation can also maintain the viability of the periodontal ligament, and preserve the alveolar bone and natural contour of soft gingival tissues. The contraindication for dental implants in young patients is another argument for autotransplantation, which can be performed in growing patients with high survival rates [11,12,47]. In these patients, transplanted teeth can erupt and move in harmony with the adjacent teeth, whereas osseointegrated implants do not erupt or move along with adjacent teeth; this can lead to infraocclusion with functional and esthetic problems. Autotransplantation is a one-stage surgical procedure and no prosthesis is required, so it is usually much cheaper than implant treatment [12].

In the present case series, the clinical outcomes of tooth autotransplantation into fresh extraction recipient sockets were analyzed. A high success rate has been reported for the autotransplantation of immature third molars [23,25,33,35]. This report supports the hypothesis that immature and mature molars can be autotransplanted to replace missing or non-restorable posterior teeth instead of implants, even though the pulp of a mature tooth cannot be completely regenerated.

We analyzed nine consecutive patients with 11 autotransplanted teeth. Survival was based on previously established criteria [10-12,38]. Presence of the transplanted tooth at the final follow-up in April 2020, clinical findings, root resorption, and bone remodeling were the main outcome measures for survival and treatment success. The survival rate was 99.1% and the success rate was 63.6%, and these rates are comparable with those reported previously in the literature [10-12,38].

Tooth loss as a result of extended caries and/or large endodontic lesions is the most common indication for autotransplantation, especially for mandibular first molars, which erupt early and often get carious. Repeated restorations with composite resin and endodontic treatment often lead to crown fractures, indicating tooth extraction. Transplantation can also be considered in cases of localized apical periodontitis, tooth agenesis, traumatic tooth loss, and atopic eruption of canines [10-12,38]. In our patient collective, the most frequent

indication for transplantation was chronic apical periodontitis, followed by non-restorable extended caries, ectopical canine eruption, hypodontia, and accidental trauma.

Successful tooth autotransplantation depends on specific patient requirements, the donor tooth, and the recipient site. Minimizing trauma to the periodontal ligament during surgery, patient age < 20 years, donor tooth with immature roots, and surgeon's experience are associated with a good prognosis [24,11,12,38]. Unsuccessful autotransplantation is usually associated with inadequate and prolonged surgical technique (trauma), donor tooth with contaminated root cementum, preoperative periodontal pocket depth  $\geq 4$  mm, and patients aged  $\geq 40$  years [24,11,12,38]. In a retrospective study on the survival of autologous tooth transplants, Yoshino et al. (2012) reported the following reasons for autotransplantation failure: periodontal attachment loss (54.9%), root resorption (26.5%), dental caries (4.0%), and root fracture (2.9%) [32].

Patient selection is important for autotransplant success because cooperation and comprehension are needed for predictable results. Candidates have to be compliant, able to follow postoperative instructions, apply sufficient oral hygiene, and be available for follow-up controls. It has been postulated that tooth autotransplantations in young patients present higher success and survival rates [24,11,12,38,41]. Higher regenerative ability of the transplanted periodontal ligament in young age favors a good prognosis. Tooth extraction and preparation of the recipient area becomes more difficult with increasing patient age because the bone mineralization density is higher. Transplantation failure in older patients could also be collated with increased chances of bacterial infection, leading to dental caries and periodontal inflammation of the donor tooth [14]. Consequently, the high survival rate seen in our study could be explained by the young age of our patients (12 to 25 years).

A suitable recipient site and appropriate donor tooth are also important for autotransplant success. In the present study, all selected patients have adequate bone levels. Adequate volume of alveolar bone in all dimensions and sufficient attached keratinized gingiva stabilizes the transplanted teeth [28]. Absence of acute infection and chronic inflammation in the recipient site also increases the success rate.

The buccolingual and mesiodistal dimensions of the donor teeth should be determined by radiography before transplantation. The buccopalatal/buccolingual and vertical bone dimensions of the recipient site are important for periodontal ligament healing. Adequate vertical bone height also improves the aesthetic outcomes [28]. Periapical infections should be thoroughly curetted during transplantation. In our cases, the recipient site was prepared before the donor tooth was harvested, in contrast to transplant techniques described in earlier studies [10,11]. In this report, most autotransplants were in the mandibular posterior region and replaced molars with a poor prognosis because of extended caries or insufficient endodontic treatment of chronic apical infection. In these cases, treatment should be planned at early stage when the poor prognosis is first detected. Preoperative bone management protocols, appropriate autotransplantation surgery, and careful postoperative endodontic monitoring are necessary.

The effect of eruption stage on the prognosis of tooth autotransplantation has been studied by Aoyama et al. [28]. They analyzed 227 erupted teeth and 32 unerupted teeth, and observed no difference in the prognosis of erupted and unerupted teeth. Unerupted third molars with incomplete root development covered by a thick follicle may be easier to extract in young patients. Traumatic injury to the root surface of the donor tooth using osteotomy burrs will impair the success of the transplant because it impairs regeneration of the periodontal ligament. The rapid cutting capacity of rotary drills and the heat they generate can damage periodontal tissue. A key factor for the success of the procedure is to maintain the viability of periodontal ligament cells in the transplanted tooth. Preserving the epithelial cell rests of Malassez prevents root resorption and maintains the periodontal ligament space, thereby preventing root ankylosis [42]. If the periodontal ligament is compromised or damaged during the surgical procedure, several types of root resorption may develop including repair-related resorption, infection-related resorption, ankylosis-related resorption, or invasive cervical resorption [36,43]. In our cases, the majority of the third molars were unerupted (63.6%), but no statistical evaluation was carried out because the sample size was small.

As mentioned above, minimally traumatic surgical extraction is the key to successful

autotransplantation [32]. During extraction and extraoral storage, great care should be taken to protect the Hertwig's epithelial root sheath and the pulp vitality. The use of burs under sterile saline irrigation to prepare the donor site is important [32,11]. In all our cases, internally cooled drills with a high-torque and low-speed hand-piece were used to prepare the recipient bed (interdentally and apically) with minimal thermal damage before harvesting the donor tooth. Care was taken not to leave any interdental bone remnants. Minimal delay between extraction and transplantation is important for maintaining periodontal membrane vitality [32,11,43]. The extraoral storage time influences the prognosis of tooth autotransplantation [14]. In the present report, the extra-alveolar time was less than 30 min (average 15 min). In most cases, additional time was required to properly adjust the donor tooth to the mesiodistal dimension of the recipient site. If further adjustment of the recipient socket is required, the donor tooth can be easily stored in its original socket. Tsukiboshi has recommended the proximal grinding of 0.5 mm of the donor tooth in some cases [18,43]. However, this maneuver increases extraoral time, requires delicate handling of the donor tooth, and can potentially damage the periodontal ligament of the donor tooth [43]. Close approximation of the donor tooth with the recipient socket wall ensures a good blood supply, thereby promoting healing and stabilization of the tooth in its new position [15]. An inadequate buccolingual width can result in alveolar ridge resorption, and insufficient buccal bone plate has been reported to contribute to treatment failure [15,24,32].

Once the transplanted tooth has been positioned, occlusional contacts should be carefully checked. The tooth should be in slight infraocclusion to allow it to erupt into proper occlusion over the next few months. With proper positioning, the tooth can be stabilized for 1 to 2 weeks [30,10,11]. A number of splinting methods have been described for stabilizing the transplanted tooth [14,18,27,34,42]. In our center, we favor a wire splinting and acid-etch composite technique. Fixation time remains controversial since long-term rigid splinting of transplanted teeth may negatively affect the healing process [34]. Bauss et al. (2002) found significantly more ankylosis and pulp necrosis in teeth fixed rigidly for 4 weeks after transplantation [35]. In our patients, splints were removed after 2 weeks of fixation in order to reduce the tooth rigidity in the recipient alveolus and therewith avoid ankylosis-related

root resorption. Because our patients followed our instructions after transplantation, we saw no need to stabilize transplanted molars using sutures only as described by Yan et al. [42].

Conventionally, the donor tooth is placed into fresh extraction sockets. However, in cases of congenitally missing teeth or early tooth loss, the recipient site has to be created surgically. The trauma caused by preparation of a new socket impairs revascularization and increases the risk of thermal damage to the bone [11]. This occurred in one case in our collective; a deciduous mandibular second molar was persistent due to agenesis of the mandibular second premolar. The transplanted tooth had to be removed almost 2 years after transplantation because of insufficient bone regeneration and extreme root resorption.

Compliance with postoperative instructions increases the chance of success and a good long-term prognosis. In our opinion, the patient's diet should be soft for 2 weeks after surgery and the patient should avoid mastication on the transplanted site. Optimal oral hygiene is also essential. Administration of antibiotics has been significantly correlated with successful outcomes of autotransplantation [41]. All our patients received antibiotics during transplantation and for 5 days postoperatively.

The stage of root development at the time of autotransplantation affects the success and survival rate of donor teeth [10-12,38,43]. Autotransplantation of teeth with immature roots is associated with increased success rates, possible pulp revascularization, maintenance of soft- and hard-tissue health and eruptive potential, and enhancement of alveolar bone compared with teeth with fully formed roots [14,10]. For vital transplants of developing teeth with open apices, endodontic treatment is not required as these teeth can be revascularized and reinnervated [43]. This concurs with a recent systematic review which concluded that the stage of root development correlated with success of the procedure [14]. The rupture of the neurovascular bundle during extraction of teeth with mature roots may reduce the possibility of revascularization, resulting in pulp necrosis [26,28]. In this situation, endodontic therapy should be performed within 15 days after transplantation to prevent inflammatory root resorption [24]. The American Association of Endodontists has recommended that pulp in teeth with close apices be extirpated 7 to 14 days

after transplantation to avoid necrotic pulp and subsequent infection causing inflammatory resorption and reducing the survival time [11]. Many studies have reported patients who refused to undergo root canal treatment after transplantation. This noncompliance probably contributed to the poorer prognosis [34]. Some have also reported extraoral root canal treatment during transplantation [25,11]. This technique is not favorable, because it significantly increases extraoral time and can damage the regenerating periodontium during instrumentation. Furthermore, transplants with completely formed roots require a greater depth at the recipient site than immature third molars do. This requires more time for preparation and careful checking to avoid encroachment on important anatomical structures, such as the mandibular canal or sinus floor, due to alveolar bone atrophy [28,30]. In fresh extraction sockets, a sufficient depth is generally obtained after simple adjustments. Root development in the first and second premolars is completed between 12 and 14 years of age [36]. This is an ideal time for autotransplantation as the premolar has erupted and attained adequate root length with a favorable crown-root ratio, while still having a sufficiently open apex to facilitate revascularization and pulp healing.

Pulp should revascularize in teeth with incomplete root formation provided that the Hertwig epithelial root sheath has not been damaged during surgery [41, 44]. Positive results for electrical pulp testing have been shown within 6 months to 1 year of transplantation [43]. This was not in concurrence with our report, in which all successful cases with incomplete root formation did not have positive pulp sensitivity test results during the follow-up period. Pulp vitality was monitored in our patients for 6 months after transplantation and annually thereafter. In our case series, five donor teeth had completely formed roots and six had incompletely formed roots, although with more than 2/3 of root length developed. However, it was not the aim of this report to examine the impact of root development on transplant success and survival of the transplanted tooth.

Tooth loss following transplantation is caused by (from most to least common) inflammatory resorption, replacement resorption (ankylosis), marginal periodontitis, apical periodontitis, caries, and trauma [43]. The mechanism of invasive cervical resorption is not well understood, but it can be treated by flap surgery or orthodontic

extrusion followed by curettage and restoration of the defect if the resorption is accessible and in its earlier stages [43]. Inflammatory resorption may become evident after 3 or 4 weeks, while replacement resorption may not become evident until 3 or 4 months after transplantation [43]. In our patients, one of the 11 transplanted teeth had to be extracted because of excessive root resorption about 2 years after transplantation (90.1% survival rate). Postoperative root resorption and absence of sufficient bone remodeling periapically was also observed in 36.3% (n = 4) of cases. Because root resorption is slow in adult patients, adult teeth will maintain their functionality for a longer time [43]. Even though the four teeth with root resorption had survived at the final follow-up, they did not fulfill the predetermined success criteria.

There are some limitations to the present case series report. We only examined nine patients with 11 transplanted teeth, which is not sufficient to draw definite conclusions about a reliable long-term surgical outcome of autotransplantation. In addition, changes in alveolar bone height and width were not analyzed through three-dimensional projection, which is a more accurate and reliable approach. The mean follow-up period of 44 months was also relatively short. An observation period of at least 10 years post-transplantation may deliver more conclusive results for comparison with results of alternative treatment options. Therefore, we did not evaluate the effects of possible risk factors such as donor tooth type, number of roots, and root development on the surgical outcome. We are still collecting follow-up data on these and other patients. A more extensive study with a standardized treatment and follow-up protocol will be the subject of another study.

Our results indicate that autologous tooth transplantation is a reasonable treatment alternative to dental implant therapy in partially edentulous, young patients, especially when performed immediately after tooth extraction. Although the indications for autotransplantation are narrow, appropriate patient selection coupled with a suitable donor tooth and recipient site can lead to exceptional esthetic and functional long-term results. However, autotransplantation has some disadvantages. It is not easy to avoid irreversible surgical trauma, it requires a donor tooth that is compatible with the recipient socket, and the long-term success rate of autotransplantation may be lower than that for osseointegrated implants. Additionally, tooth

autotransplantation cannot be applied in every maxillary and mandibular region. Endodontic therapy may also be required if donor teeth have fully developed roots. Furthermore, complications such as ankylosis- and infection-related root resorption may occur [43].

Current treatments are being tested to improve the surgical outcome. Guided bone regeneration could optimize functional outcomes in patients with extensive buccolingual alveolar bone atrophy [29]. However, some authors argue that the use of free bone autografts to autotransplant teeth with incomplete root development may negatively influence the treatment outcome because blood supply is impaired through diffusion [38]. Modified surgical techniques to ensure the minimally traumatic removal of donor teeth can also increase the success rate of autotransplantation [15,45,46]. Piezoelectric surgery with specific device tip vibration frequencies has been advocated to facilitate the osteotomy of unerupted third molars with minimal trauma to periodontal fibers or bud follicles and to reduce ankylosis or root resorption of the transplanted teeth [39]. Recently, cone beam computer tomography based stereolithographic surgical guides for autotransplant of teeth have been used [46]. This technique is excellent in reducing the extraoral time, but its routine use is restricted by availability and cost.

For the future, a set of criteria for evaluating the success or failure of autotransplantation needs to be established. Tooth transplantation in children and adolescents should be organized by surgeons, orthodontics, and pediatric dentists. The immediate, short-term and long-term outcomes need to be explained to every patient, together with alternative treatment options. Autotransplantation may be suited to patients with limited financial resources, in public health services, and for restoration of function and aesthetics in growing patients. However, despite increased research on this topic, there are no evidence-based guidelines or protocols relating to autologous tooth transplantation. Future studies should focus on: (i) long-term survival rates, (ii) limitation of this treatment option in younger patients, and (iii) endodontic treatment for transplanted mature donor teeth and when this treatment should be given.

## 5. CONCLUSION

Our case series report suggests that tooth autotransplantation is a valuable alternative

therapy option especially in young individuals. It may also be a temporary treatment. The transplant can replace missing teeth or teeth with poor prognosis to ensure preservation of alveolar bone until growth has ceased and then, if necessary, the patient can receive an implant. Through proper case selection, adequate preparation of the recipient site and minimizing iatrogenic trauma during donor tooth extraction, high success rates are ensured. Although this method has not been established as a traditional means of replacing lost teeth, the procedure deserves more consideration in the future.

## CONSENT

For this non-interventional observational retrospective study, patient data were referenced to with the understanding and written consent of the patient, and all data were also anonymized and de-identified prior to analysis. In case of non-adults, the written consent was given by one of the parents. Full compliance with data protection and safeguarding of data was ensured and no information which could identify the patients was collected. Reporting was based on the recommendations of the Strengthening the Reporting of Observational Studies in Epidemiology (STROBE) initiative [47].

## ETHICAL APPROVAL

All procedures performed in our clinic were in accordance with the ethical standards of the institutional research committee as well as with the 1964 Helsinki declaration and its later amendments or comparable ethical standards. An extra approval of the local Ethics Committee was not obtained.

## ACKNOWLEDGEMENTS

We would like to thank Bacon Editing® for language editing of this manuscript.

## COMPETING INTERESTS

Authors have declared that no competing interests exist.

## REFERENCES

1. Fong CC. Transplantation of the third molar. *Oral Surg Oral Med Oral Pathol.* 1953;6(8):917-926.
2. Hale ML. Autogenous transplants. *Oral Surg Oral Med Oral Pathol.* 1956;9:76-83.
3. Slagsvold O, Bjercke B. Indications for autotransplantation in cases of missing premolars. *Am J Orthod.* 1978;74:241–257.
4. Slagsvold O, Bjercke B. Applicability of autotransplantation in cases of missing upper anterior teeth. *Am J Orthod.* 1978;74:410–421.
5. Yan Q, Li B, Long X. Immediate autotransplantation of mandibular third molar in China. *Oral Surg Oral Med Oral Pathol Oral Radiol Endod.* 2010;110:436-440.
6. Akkocaoglu M, Kasaboglu O. Success rate of autotransplanted teeth without stabilisation by splints: a long-term clinical and radiological follow-up. *Br J Oral Maxillofac Surg.* 2005;43:31-35.
7. Bae J, Choi Y, Cho B, Kim Y, Kim S. Autotransplantation of teeth with complete root formation: a case series. *J Endod.* 2010;36:1422-1426.
8. Watanabe Y, Mohri T, Takeyama M, et al. Long-term observation of autotransplanted teeth with complete root formation in orthodontic patients. *Am J Orthod Dentofac Orthop.* 2010;138:720-726.
9. Huth K, Nazet M. Autotransplantation and surgical uprighting of impacted or retained teeth: a retrospective clinical study and evaluation of patient satisfaction. *Acta Odontol Scand.* 2013;71:1538-1546.
10. Machado LA, do Nascimento RR, Ferreira DM, Mattos CT, Vilella OV. Long-term prognosis of tooth autotransplantation: A systematic review and meta-analysis. *Int J Oral Maxillofac Surg* 2016;45(5):610-617.
11. Yu HJ, Jia P, Lv Z, Qiu LX. Autotransplantation of third molars with completely formed roots into surgically created sockets and fresh extraction sockets: a 10-year comparative study. *Int J Oral Maxillofac Surg.* 2017;46(4):531-538.
12. Armstrong L, O'Reilly C, Ahmed B. Autotransplantation of third molars: a literature review and preliminary protocols. *Br Dent J.* 2020;228(4):247-251.
13. Cross D, El-Angbawi A, McLaughlin P, Keightley A, Brocklebank L, Whitters J, McKerlie R, Cross L, Welbury R. Developments in autotransplantation of teeth. *Surgeon.* 2013;11:49-55.
14. Nagori SA, Bhutia O, Roychoudhury A, Pandey RM. Immediate autotransplantation of third molars: an experience of 57 cases. *Oral Surg Oral*



- Med Oral Pathol Oral Radiol. 2014; 118(4):400-407.
15. Lee S-J, Kim E. Minimizing the extra-oral time in autogeneous tooth transplantation: use of computer-aided rapid prototyping (CARP) as a duplicate model tooth. *Restor Dent Endod.* 2012;37:136-141.
  16. Czochrowska EM, Stenvik A, Album B, Zachrisson BU. Autotransplantation of premolars to replace maxillary incisors: a comparison with natural incisors. *Am J Orthod Dentofacial Orthop.* 2000;118:592-600.
  17. Kallu R, Vinckier F, Politis C, Mwalili S, Willems G. Tooth transplantations: a descriptive retrospective study. *Int J Oral Maxillofac Surg.* 2005;34:745-755.
  18. Tsukiboshi M. Autotransplantation of teeth: requirements for predictable success. *Dent Traumatol.* 2002;18:157-180.
  19. Tsukiboshi M, Andreasen JO, Asai L, Bakland LK, Wilson TG. *Autotransplantation of Teeth.* Chicago, IL: Quintessence Pub Co; 2001.
  20. Gonzalez-Ocasio J, Stevens M. Autotransplantation of Third Molars With Platelet-Rich Plasma for Immediate Replacement of Extracted Non-Restorable Teeth: A Case Series. *J Oral Maxillofac Surg.* 2017;75(9):1833.e1-1833.e6.
  21. Czochrowska EM, Stenvik A, Bjercke B, Zachrisson BU. Outcome of tooth transplantation: survival and success rates 17-41 years posttreatment. *Am J Orthod Dentofac Orthop.* 2002;121:110-119.
  22. Kvint S, Lindsten R, Magnusson A, Nilsson P, Bjerklin K. Autotransplantation of teeth in 215 patients. *Angle Orthod.* 2010;80:446-451.
  23. Bauss O, Engelke W, Fenske C, Schilke R, Schwestka-Polly R. Autotransplantation of immature third molars into edentulous and atrophied jaw sections. *Int J Oral Maxillofac Surg.* 2004;33:558-563.
  24. Sugai T, Yoshizawa M, Kobayashi T, Ono K, Takagi R, Kitamura N, et al. Clinical study on prognostic factors for autotransplantation of teeth with complete root formation. *Int J Oral Maxillofac Surg.* 2010;39:1193-203.
  25. Bauss O, Zonios I, Engelke W. Effect of additional surgical procedures on root development of transplanted immature third molars. *Int J Oral Maxillofac Surg.* 2008;37:730-735.
  26. Akiyama Y, Fukuda H, Hashimoto K. A clinical and radiographic study of 25 auto-transplanted third molars. *J Oral Rehabil.* 1998;25:640-644.
  27. Ko JM, Paik CH, Choi S, Baek SH. A patient with protrusion and multiple missing teeth treated with autotransplantation and space closure. *Angle Orthod.* 2014;84:561-567.
  28. Aoyama S, Yoshizawa M, Niimi K, Sugai T, Kitamura N, Saito C. Prognostic factors for autotransplantation of teeth with complete root formation. *Oral Surg Oral Med Oral Pathol Oral Radiol.* 2012;114:216-228.
  29. Yu HJ, Qiu LX, Wang XZ. Long-term follow-up of autogenous canine transplants with application of guided bone regeneration. *Int J Oral Maxillofac Surg.* 2014;43:355-361.
  30. Mejare B, Wannfors K, Jansson L. A prospective study on transplantation of third molars with complete root formation. *Oral Surg Oral Med Oral Pathol Oral Radiol Endod.* 2004;97:231-238.
  31. Tsurumachi T, Kakehashi Y. Autotransplantation of a maxillary third molar to replace a maxillary premolar with vertical root fracture. *Int Endod J.* 2007;40:970-978.
  32. Yoshino K, Kariya N, Namura D, Noji I, Mitsuhashi K, Kimura H, et al. Risk factors affecting third molar autotransplantation in males: a retrospective survey in dental clinics. *J Oral Rehabil.* 2012;39:821-829.
  33. Bauss O, Zonios I, Rahman A. Root development of immature third molars transplanted to surgically created sockets. *J Oral Maxillofac Surg.* 2008;66:1200-1211.
  34. Bauss O, Schwestka-Polly R, Schilke R, Kiliaridis S. Effect of different splinting methods and fixation periods on root development of autotransplanted immature third molars. *J Oral Maxillofac Surg.* 2005;63:304-310.
  35. Bauss O, Schilke R, Fenske C, Engelke W, Kiliaridis S. Autotransplantation of immature third molars: influence of different splinting methods and fixation periods. *Dent Traumatol.* 2002;18:322-328.
  36. Kristerson L, Andreasen JO. Influence of root development on periodontal and pulpal healing after replantation of incisors in monkeys. *Int J Oral Surg.* 1984; 13(4):313-323.
  37. Bae JH, Choi YH, Cho BH, Kim YK, Kim SG. Autotransplantation of teeth with complete root formation: a case series. *J Endod.* 2010;36:1422-1426.

38. Almpiani K., Papageorgiou SN, Papadopoulos MA. Autotransplantation of teeth in humans: a systematic review and meta-analysis. Clin Oral Invest. 2015;19:1157-1179.
39. Koszowski R, Morawiec T, Bubiłek-Bogacz A. Use of the piezosurgery technique for cutting bones in the autotransplantation of unerupted third molars. Int J Periodontics Restor Dent. 2013;33:477-481.
40. Kingsmill VJ. Post-extraction remodeling of the adult mandible. Crit Rev Oral Biol Med. 1999;10:384-404.
41. Kafourou V, Tong HJ, Day P, Houghton N, Spencer RJ, Duggal M. Outcomes and prognostic factors that influence the success of tooth autotransplantation in children and adolescents. Dent Traumatol. 2017;33(5):393-399.
42. Yan Q, Li B, Long X. Immediate autotransplantation of mandibular third molar in China. Oral Surg Oral Med Oral Pathol Oral Radiol Endod. 2010;110(4):436-40.
43. Tsukiboshi M, Yamauchi N, Tsukiboshi Y. Long-term outcomes of autotransplantation of teeth: A case series. Dent Traumatol. 2019; 35(6):358-367.
44. Struys T, Schuermans J, Corpas L, Politis C, Vrielinck L, Schepers S, Jacobs R, Ivo L. Proliferation of epithelial rests of Malassez following auto-transplantation of third molars: a case report. J Med Case Rep. 2010 19;4:328.
45. Shahbazian M, Jacobs R, Wyatt J, Denys D, Lambrichts I, Vinckier F, et al. Validation of the cone beam computed tomography-based stereolithographic surgical guide aiding autotransplantation of teeth: clinical case– control study. Oral Surg Oral Med Oral Pathol Oral Radiol. 2013;115:667-675.
46. Abella F, Ribas F, Roig M, González Sánchez JA, Durán-Sindreu F. Outcome of Autotransplantation of Mature Third Molars Using 3-dimensional-printed Guiding Templates and Donor Tooth Replicas. J Endod. 2018;44(10):1567-1574.
47. Vandembroucke JP, von Elm E, Altman DG, Gøtzsche PC, Mulrow CD, Pocock SJ, Poole C, Schlesselman JJ, Egger M: STROBE Initiative. Strengthening the Reporting of Observational Studies in Epidemiology (STROBE): explanation and elaboration. Int J Surg. 12:1500-1524, 2014.

© 2021 Sakkas et al.; This is an Open Access article distributed under the terms of the Creative Commons Attribution License (<http://creativecommons.org/licenses/by/4.0>), which permits unrestricted use, distribution, and reproduction in any medium, provided the original work is properly cited.

*Peer-review history:*

*The peer review history for this paper can be accessed here:*  
<https://www.sdiarticle5.com/review-history/81104>