

Mechanical Tooth Depuration and Pocket Depth: A Correlative Clinical Study

Anika Daing^{1*} • Aparna Singh² • Jaya Dixit³

¹Assistant Professor, Department of Periodontology, Faculty of Dentistry, Jamia Millia Islamia, New Delhi, India

²Senior Resident, Department of Periodontology, Faculty of Dental Sciences, King George Medical College, Lucknow, Uttar Pradesh, India

³Head, Department of Periodontology, Faculty of Dental Sciences, Chhatrapati Maharaj Medical University (KGMU), Lucknow Uttar Pradesh, India

*Corresponding Author; E-mail: girldentist@rocketmail.com

Received: 7 July 2014; Accepted: 5 February 2015

J Periodontol Implant Dent 2015;7(1):15–20 | doi: 10.15171/jpid.2015.003

This article is available from: <http://dentistry.tbzmed.ac.ir/jpid>

© 2015 The Authors; Tabriz University of Medical Sciences

This is an Open Access article distributed under the terms of the Creative Commons Attribution License (<http://creativecommons.org/licenses/by/3.0>), which permits unrestricted use, distribution, and reproduction in any medium, provided the original work is properly cited.

Abstract

Background and aims. Previous researches, conducted mostly on extracted teeth, have shown that efficacy of calculus removal decreases with increasing pocket depth, but there is still a lack of clinical studies concerning the correlation between residual calculus and varying pocket depths. The objective of the present clinical study was to assess the efficiency of mechanical tooth depuration by closed approach in terms of pocket depth, tooth type and tooth surface.

Materials and methods. Fifty subjects with chronic periodontitis underwent scaling and root planing by closed approach. After instrumentation, 225 teeth (92 single-rooted and 133 multi-rooted) with pocket depths of 4 mm and 5–8 mm were evaluated for calculus-positive surfaces by surgical flap elevation. Residual calculus was assigned a score from 1 to 3 based on the distance in mm from CEJ or furcation.

Results. 11.4% of surfaces were calculus-positive. On inter-pocket depth comparison, calculus-positive surfaces were present in both single- and multi-rooted teeth, with no significant differences. Residual calculus score 1 was significantly associated with a pocket depth of 4 mm and scores 2 and 3 with pocket depths 5–8 mm in overall distribution and for multi-rooted teeth.

Conclusion. During mechanical tooth depuration by closed approach, no significant correlation was found between percentages of calculus-positive surfaces and increasing pocket depth.

Key words: Tooth depuration, pocket depth, calculus.

Introduction

Calculus is almost always covered by a layer of plaque.¹ Previous research has shown that both

sterilized and unsterilized calculi are capable of initiating an immuno-inflammatory response.² Presence of calculus even after thorough mechanical tooth depuration (scaling and root planing) provides a hin-

drance to the regeneration of periodontal tissues. Therefore, its removal is the first step in the chronological sequence of periodontal treatment. It has been reported that small areas of calculus are often left behind with anywhere from 3% to 80% of instrumented root surfaces with varying pocket depths from 3 to 8 mm.³⁻¹¹ The core of the present study is to assess the efficiency of mechanical tooth depuration by closed approach in terms of pocket depth, tooth type and tooth surface.

Materials and Methods

Selection of Subjects

Fifty subjects with chronic periodontitis were recruited from the Outpatient Department of Periodontology, Faculty of Dental Sciences, Chhatrapati Shahuji Maharaj Medical University, Lucknow, Uttar Pradesh, India. The subjects were selected based on the following inclusion criteria: non-compromised systemic health, presence of subgingival calculus and probing pocket depth of ≥ 4 mm. Exclusion criteria: teeth with root surface caries or any subgingivally placed restoration, tooth/teeth with gingival recession and subjects undergone periodontal surgery within the last 6 months. All the subjects were informed about the study and were asked to sign a written informed consent form. The study protocol was approved by the Ethics Board of the institution.

Clinical Parameters

Pre-treatment: Probing pocket depth: It was recorded at baseline with the help of a UNC-15 periodontal probe at six sites around each tooth (buccal, lingual, mesiobuccal, mesiolingual, distobuccal and distolingual).

Post-treatment (After scaling root planing): (I) Calculus-positive surface score: measurements were taken from the cemento-enamel junction (CEJ) to the apical border of the calculus on the instrumented root surface and scores were assigned as follows:

Score 0=no calculus

Score 1=calculus at CEJ or ≤ 1 mm from the CEJ

Score 2=calculus >1 mm and ≤ 3 mm from the CEJ

Score 3=calculus >3 mm from the CEJ.

The final analysis was based on four surfaces of buccal, lingual, mesial (mesiobuccal+mesiolingual) and distal (distobuccal and distolingual).

(II) Furcation score: Measurements were taken from the furcation entrance to the apical border of the calculus with the UNC-15 periodontal probe and the following scores were assigned:

Score 0 =no calculus

Score 1=calculus at the furcation entrance or ≤ 1 mm from the furcation entrance

Score 2=calculus >1 mm and ≤ 3 mm from the furcation entrance

Score 3=calculus >3 mm from the furcation entrance

All the pre-treatment and post-treatment recordings were carried out by a single trained examiner.

Instrumentation

All the subjects included in the study underwent a meticulous mechanical tooth depuration with the help of scalers and area-specific curettes until the root surface felt smooth and glass hard to the explorer. The subjects were instructed in oral hygiene procedures and were recalled after 4 weeks for re-evaluation of probing pocket depths. Teeth with probing pocket depths of 4–8 mm were considered only.

Dental Population

A total of 225 teeth (92 single-rooted and 133 multi-rooted) were included.

Surgical Procedure

After 4 weeks, flap surgery was planned only in those areas with probing pocket depths of ≥ 4 mm. The segment involved was anesthetized with 2% lignocaine with 1:80,000 adrenaline. The flap was elevated to gain access to root surfaces. After removal of granulation tissue, each of the six root surfaces was carefully examined for the calculus-positive tooth surfaces. When calculus was detected, its location on the root and distances in millimeters from the CEJ or furcation was determined. The left-over calculus was then removed and the surgical area was thoroughly debrided. The flap was then repositioned against the root surface, sutured with 3-0 silk sutures and periodontal dressing was given. Medications and postoperative instructions were given and the subjects were recalled after 7 days for the removal of sutures.

Statistical Analysis

Data was analyzed using SPSS 17.0. Association between calculus-positive tooth surfaces and varying pocket depths were compared using chi-squared test. Scorewise distribution (ordinal differences) of calculus-positive surfaces was compared in relation to different pocket depths using Mann-Whitney U test. The confidence level of the study was kept at 95%, hence a "p" value less than 0.05 indicated statistically significant differences.

Results

In overall distribution it was found that a total of 11.4% (103 out of 900) surfaces were calculus-positive (Table 1). Individually for single- and multi-rooted teeth 10.8% (40 out of 368) and 11.84% (63 out of 532) of surfaces were respectively calculus-positive. Furthermore, on inter-pocket depth comparison, calculus-positive surfaces were present in both single- and multi-rooted teeth, with no significant differences ($P>0.05$). Maximum mesial surfaces were calculus-positive as compared to other surfaces and this trend was maintained for both pocket depths of 4 mm and 5–8 mm in single- and multi-rooted teeth. 88.9% of surfaces with a pocket depth of 4 mm and 88.3% of surfaces with a pocket depth of 5–8 mm were calculus-negative (Table 1).

Significant association ($P<0.001$) of score 1 was observed in overall 30 surfaces and on 14 surfaces of multi-rooted teeth with a pocket depth of 4 mm (Table 2). Unlike score 1, scores 2 and 3 were significant in pocket depths of 5–8 mm in both overall distribution and on multi-rooted teeth. Insignificant distribution ($P=0.105$) of scores 1, 2 and 3 were present on inter-pocket depth comparison in single-rooted teeth. However, distribution of calculus scores were significant ($P < 0.01$) when single-rooted teeth were compared with multi-rooted teeth.

91.73% of furcations were calculus-negative (Figure 1). Amongst the 8.27% calculus-positive furcations, score 3 was present in 3.76% of furcations followed by score 1 (3.01%) and score 2 (1.50%).

Discussion

In 1886, G.V. Black gave the vision that “the most important measure in the treatment of calcic inflammation of periodontal membrane and gums is the removal of the concretions from the teeth and next an arousing in the minds of the patient of an active

determination to keep them clean in future.”¹² This statement is as true today as it was in 1886 because even now scaling and root planing remains an essential part of successful periodontal therapy.

Studies in the periodontal literature have addressed the question of predictability of subgingival instrumentation and have reported that the efficacy of calculus removal decreases substantially with increasing pocket depth.^{3–8,13} However, these findings were mostly based on research conducted on extracted teeth, and there is still a paucity of clinical studies concerning this. Teeth with pocket depths of ≥ 4 mm were selected for the present clinical study as previous reports have shown that complete removal of calculus is more predictable in probing pocket depths of ≥ 3 mm.⁵ Evaluation of the calculus-positive surfaces was based on visual inspection. This open approach method was less liable to the errors inherent in the subjective judgment and also had advantages of being objective, quick and easy in locating and assessing the calculus-positive surfaces in terms of probing depth. Detection of calculus beyond the visual limit was not attempted in this clinical study. This method of scoring was in agreement with that of Gelin et al¹⁴ but was different from several other studies where residual calculus was detected under a stereomicroscope after extraction of teeth.^{5–9,13,15,16}

In the present study a total of 11.4% of surfaces were calculus-positive after meticulous mechanical tooth depuration (Table 1). Jones & O’Leary,¹⁷ Sherman et al,⁹ Buchanan et al,⁷ Gelin et al¹⁴ and Brayer et al⁸ also reported that 18.75%, 19%, 24%, 26.8% and 32.5% of surfaces had residual calculus in their respective studies. Fujikawa et al¹⁸ observed histologically that out of 100 roots 10% showed residual calculus. Barnes & Schaffer,¹⁹ and Chan & Needleman²⁰ reported in their studies that 95% and 85% of the calculus was removed by hand scaling. Almost similar results were obtained in our study

Table 1. Percentage distributions of calculus-positive tooth surfaces on 225 teeth in different pocket depths

Pocket depth in mm	Tooth surfaces				Total
	Buccal	Mesial	Lingual	Distal	
Overall (No. of teeth = 225; No. of surfaces=900)					
4 mm (n=360)	7 (1.94%)	16 (4.4%)	8 (2.2%)	9 (2.5%)	40 (11.1%)
5–8 mm (n=540)	10 (1.85%)	29 (5.40%)	7 (1.3%)	17 (3.1%)	63 (11.7%)
$\chi^2=0.066$ (df=1); $p=0.798$					
Single-rooted (No. of teeth = 92; No. of surfaces=368)					
4 mm (n=152)	3 (1.97%)	8 (5.3%)	2 (1.3%)	5 (3.3%)	18 (11.8%)
5–8 mm (n=216)	4 (1.9%)	11 (5.1%)	3 (1.39%)	4 (1.9%)	22 (10.2%)
$\chi^2=0.253$ (df=1); $p=0.615$					
Multi-rooted (No. of teeth = 133; No. of surfaces=532)					
4 mm (n=208)	4 (1.92%)	8 (3.8%)	4 (1.92%)	6 (2.9%)	22 (10.6%)
5–8 mm (n=324)	6 (1.85%)	18 (5.6%)	5 (1.54%)	12 (3.7%)	41 (12.7%)
$\chi^2=0.524$ (df=1); $p=0.469$					

*A total of 1350 surfaces of 225 teeth were examined (six surfaces per tooth: buccal, mesiobuccal, mesiolingual, distal, distobuccal, distolingual); the final analysis was based on 900 surfaces (four surfaces per tooth: buccal, mesial, lingual and distal).

with 88.6% of surfaces being calculus-negative.

A trend of more calculus-positive mesial surfaces (overall = 9.80%, single-rooted = 10.4% and multi-rooted = 9.4%) was observed as compared to other surfaces (Table 1). No association could be established between total calculus-positive surfaces and pocket depths because of a minimal difference in percentages of 0.6%, 1.6% and 2.1% in pocket depths of 4 mm and 5–8 mm in overall, single-rooted and multi-rooted teeth, respectively (Table 1). Frisch et al,²¹ Breinger et al,²² Sherman et al⁹ and Nagy et al¹⁵ also believed that the amount of remaining root calculus was not dependent on the pocket depth. In contrast Waerhaug et al,⁴ Rabbani et al,⁵ Caffesse et al,⁶ Buchanan et al,⁷ Brayer et al,⁸ and Fliescher et al¹³ found a direct relationship between probing pocket depth and residual calculus.

Overall as well as in multi-rooted teeth, a significant association was observed between calculus scores and pocket depths (Table 2). In an overall distribution of calculus score, 75% of surfaces with a pocket depth of 4 mm revealed score 1 calculus in comparison to 33.3% in 5–8-mm pockets. In multi-rooted teeth, out of 22 surfaces 14 surfaces (63.6%) displayed score 1. With increasing depth of pocket (5–8 mm) the percentage (19.5%) of residual calculus score 1 decreased. An inverse trend was observed for higher calculus scores (score 2 and score 3) in 5–8-mm pocket area. A large percentage of calculus deposits in coronal pocket areas near CEJ were also reported by Breininger et al.²² Gurgan et al²³ also found more significant calculus deposits in the coronal third of root surfaces as compared to the middle third. Though a similar trend was present in scorewise distribution in relation to pocket depth for single-rooted teeth, the results were non-significant ($P=0.105$). Similar findings were observed for multi-rooted teeth in a study conducted by Buchnan et al⁷ whereas Rabbani et al⁵ and Caffesse et al⁶ reported no significant differences in percentages of residual

calculus between anterior and posterior teeth.

No conclusive results could be ascertained in case of furcation as 122 out of 133 teeth were of incipient type and only 11 showed frank furcations (Figure 1). Out of these 11 teeth, calculus score 3 was most frequent in 5 teeth (3.76%). In sharp contrast to our study, Wylam et al²⁴ found 93.2% calculus deposits in furcations treated with closed scaling and root planing and Fleischer et al¹³ also reported calculus-free furcations in only 5% of the non-surgically treated teeth.

The desired goal of mechanical tooth depuration is to eliminate all the calcified deposits from periodontally involved root surfaces to reach a therapeutic goal of a clean, smooth surface. A study by Waerhaug⁴ demonstrated that plaque covering calculus is irritating to gingiva than the plaque alone. However, none of the studies to date, including our present study, showed 100% calculus-negative surfaces. Complete removal of calculus was unattainable even in a pocket depth of 4 mm, which could be attributed to factors related to root topography, morphology of calculus and lack of tactile sensitivity in detection of calculus. Walker & Ash²⁵ reported questionable ability to clinically detect subgingival calculus by subjective methods like the use of an explorer or a curette. Microscopically explorer tip used to evaluate the root surfaces is actually larger than the edge height of the burnished residual calculus, which makes the clinical ability to detect small step differences between calculus and root surface extremely difficult. Sherman et al⁹ showed that clinically only 19% of residual calculus was detected; however, on microscopic examination 58% of surfaces were positive for calculus. Michaud et al¹⁶ documented a residual calculus of 15.7% despite the use of periodontal endoscope for scaling and root planing.

Based on these findings, for complete removal of calculus it will be more rational to opt for an open mechanical tooth depuration even in 4-mm-deep

Table 2. Scorewise distributions of calculus-positive surfaces in relation to different pocket depths

Pocket Depth	Score		
	1	2	3
Overall (n=103 surfaces)			
4 mm (n=40)	30 (75%)	10 (25%)	0
5–8 mm (n=63)	21 (33.3%)	29 (46.0%)	13 (20.6%)
z=4.402; p<0.001			
Single-rooted (n=40 surfaces)			
4 mm (n=18)	16 (88.9%)	2 (11.1%)	0
5–8 mm (n=22)	13 (59.1%)	8 (36.4%)	1 (4.5%)
z=2.099; p=0.105			
Multi-rooted (n=63 surfaces)			
4 mm (n=22)	14 (63.6%)	8(36.4%)	0
5–8 mm (n=41)	8 (19.5%)	21(51.2%)	12 (29.3%)
z=3.855; p<0.001			

Single-rooted vs multi-rooted: $z=3.663$, $p<0.01$

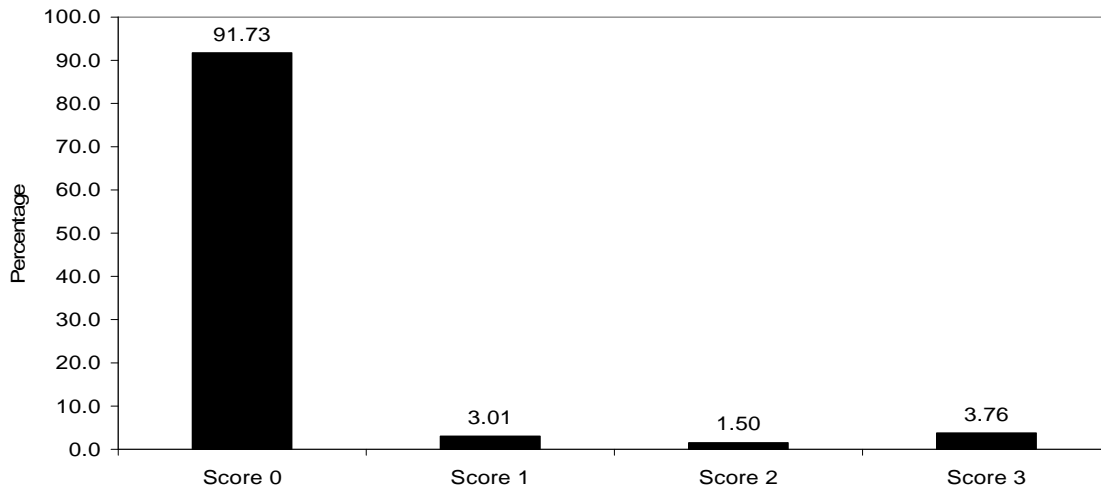


Figure 1. Scorewise percentage distributions of calculus-positive furcations in 133 multi-rooted teeth.

pockets. This will avoid unnecessary harm to healthy root structures by over-instrumentation, will obviate the increased time and patient fatigue, and would result in a more clinically acceptable root surface.

Conclusion

To conclude, within the limits of this study, no correlation was found between the percentages of calculus-positive surfaces and increasing pocket depth on mechanical tooth depuration by closed approach. Distribution of calculus scores was significant with more coronal calculus deposits near CEJ (score 1) for 4-mm pockets and higher scores of 2 and 3 for pocket depths of 5–8 mm. Mesial surfaces were maximally calculus-positive as compared to other surfaces. Tooth type influenced calculus score distribution, with significance for multi-rooted teeth. Relation between residual calculus deposits and pocket depth could not be ascertained for furcations as 91.73% were of incipient type.

References

1. Roberts-Harry EA, Clerehugh V. Subgingival calculus: where are we now? A comparative review. *J Dent* 2000; 28:93-102. doi: [10.1016/s0300-5712\(99\)00056-1](https://doi.org/10.1016/s0300-5712(99)00056-1)
2. Allen D, Kerr D. Tissue response in the guinea pig to sterile and non sterile calculus. *J Periodontol* 1965; 6: 177-187.
3. Lovdøl A, Arno A, Schei O, Waerhaug J. Combined effect of subgingival scaling and controlled oral hygiene on the incidence of gingivitis. *Acta Odontol Scand* 1961;19:537-5. doi: [10.3109/00016356109043406](https://doi.org/10.3109/00016356109043406)
4. Waerhaug J. Healing of the dento epithelial junction following subgingival plaque control. II: as observed on extracted teeth. *J Periodontol* 1978;49:119-34. doi: [10.1902/jop.1978.49.3.119](https://doi.org/10.1902/jop.1978.49.3.119)
5. Rabbani GM, Ash M, Caffesse RG. The effectiveness of subgingival scaling and root planing in calculus removal. *J Periodontol* 1981;52:119-23. doi: [10.1902/jop.1981.52.3.119](https://doi.org/10.1902/jop.1981.52.3.119)
6. Caffesse RG, Sweeney PL, Smith BA. Scaling and root planing with and without periodontal flap surgery. *J Clin Periodontol* 1986;13:205-10. doi: [10.1111/j.1600-051x.1986.tb01461.x](https://doi.org/10.1111/j.1600-051x.1986.tb01461.x)
7. Buchanan SA, Robertson PB. Calculus removal by scaling and root planing with and without surgical access. *J Periodontol* 1987;58:159–63. doi: [10.1902/jop.1987.58.3.159](https://doi.org/10.1902/jop.1987.58.3.159)
8. Brayer WK, Mellonig JT, Dunlap RM, Marinak KW, Carson RE. Scaling and root planing effectiveness: the effect of root surface access and operator experience. *J Periodontol* 1989;60:67-72. doi: [10.1902/jop.1989.60.1.67](https://doi.org/10.1902/jop.1989.60.1.67)
9. Sherman PR, Hutchens LH Jr, Jewson LG. The effectiveness of subgingival scaling and root planning. I. Clinical detection of residual calculus. *J Periodontol* 1990;61:9–15. doi: [10.1902/jop.1990.61.1.9](https://doi.org/10.1902/jop.1990.61.1.9)
10. Rateitschak-Pluss EM, Schwarz JP, Guggenheim R. Non surgical periodontal treatment: Where are the limits? An SEM study. *J Clin Periodontol* 1992;19:240–4. doi: [10.1111/j.1600-051x.1992.tb00460.x](https://doi.org/10.1111/j.1600-051x.1992.tb00460.x)
11. Van der Velden U. Errors in the assessment of pocket depth in vitro. *J Clin Periodontol* 1978;5:182-7.
12. Black GV. *Prognosis Diseases of periodontal ligament. The American System of Dentistry*. Philadelphia: Lea Brothers & Co.; 1986.
13. Fleischer HC, Mellonig JT, Brayer WK, Gray JL, Barnett JD. Scaling and root planning efficacy in multirrooted teeth. *J Periodontol* 1989;60:402-9. doi: [10.1902/jop.1989.60.7.402](https://doi.org/10.1902/jop.1989.60.7.402)
14. Gelin RG, Miller ML, Javed T, Engier W, Mishkin DJ. The effectiveness of the Titan S –Sonic scaler versus curettes in the removal of subgingival calculus. A human surgical evaluation. *J Periodontol* 1986;57:672-680. doi: [10.1902/jop.1986.57.11.672](https://doi.org/10.1902/jop.1986.57.11.672)
15. Nagy RJ, Corgel JO, Stambaugh R. The effectiveness of Scaling and root planning with curets designed for deep pockets. *J Periodontol* 1992;63:954-9. doi: [10.1902/jop.1992.63.12.954](https://doi.org/10.1902/jop.1992.63.12.954)
16. Michaud RM, Schoolfield, Mellonig JT, Mealey BL. The efficacy of subgingival calculus removal with endoscopy-aided scaling and root planning: A study on multirrooted teeth. *J Periodontol* 2007;78:2238-45. doi: [10.1902/jop.2007.070251](https://doi.org/10.1902/jop.2007.070251)

20 Daing et al.

17. Jones WA, O'Leary TJ. The effectiveness *in vivo* root planing removing bacterial endotoxin from the root of periodontally involved teeth. *J Periodontol* 1978;49:337-42. doi: [10.1902/jop.1978.49.7.337](https://doi.org/10.1902/jop.1978.49.7.337)
18. Fujikawa K, O'Leary TJ, Kafrauf AH. The effect of retained subgingival calculus on healing after flap surgery. *J Periodontol* 1988;59:170-5. doi: [10.1902/jop.1988.59.3.170](https://doi.org/10.1902/jop.1988.59.3.170)
19. Barnes JE, Schaffer EM. Subgingival root planing—a comparison using files, hoes and curettes. *J Clin Periodontol* 1960;35:300.
20. Chan YK, Needelman IG, Clifford LR. Comparison of four methods of assessing root surface debridement. *J Periodontol* 2000;71:385-93.
21. Frisch J, Levin MP, Bhaskar SN. Calculus removal effectiveness of scaling. *J South Cal Dent Assoc* 1970;38:36-8.
22. BreiningerDR, O'LearyTJ, Blumenshine RVH. Comparison effectiveness of ultrasonic and hand scaling for the removal of subgingival plaque and calculus. *J Periodontol* 1987;58:9-18. doi: [10.1902/jop.1987.58.1.9](https://doi.org/10.1902/jop.1987.58.1.9)
23. Gurgan CA, Bilgrin E. Distribution of different morphologic types of subgingival calculus on proximal root surfaces. *Quintessence Int* 2005;36:202-8.
24. Wylam JM, Mealey BL, Mills MP, Waldrop TC, Moskowitz DC. The clinical effectiveness of open versus closed scaling and root planing in multirooted teeth. *J Periodontol* 1993;64:1023-8. doi: [10.1902/jop.1993.64.11.1023](https://doi.org/10.1902/jop.1993.64.11.1023)
25. Walker SL, Ash M. A study of root planing by scanning electronic microscopy. *Dent Hyg* 1976;50:109-14.